

Chapter 19. ACUTE AND SUBACUTE, AND RIEDEL'S THYROIDITIS

Rupendra T. Shrestha, M.D. Division of Endocrinology, Diabetes and Metabolism, University of Minnesota, Minneapolis MN, USA

James V. Hennessey, M.D. FACP Division of Endocrinology, Beth Israel Deaconess Medical Center, Harvard Medical School, Boston MA, USA

Revised 31 December 2015

ABSTRACT

The thyroid, like any other structure, may be the seat of an acute or chronic suppurative or non-suppurative inflammation. Various systemic infiltrative disorders may leave their mark on the thyroid gland as well as elsewhere. Infectious thyroiditis is a rare condition, usually the result of bacterial invasion of the gland. Its signs are the classic ones of inflammation: heat, pain, redness, and swelling, and special ones conditioned by local relationships, such as dysphagia and a desire to keep the head flexed on the chest in order to relax the paratracheal muscles. The treatment is that for any febrile disease, including specific antibiotic drugs if the invading organism has been identified and its sensitivity to the drug established. Otherwise, a broad-spectrum antibiotic may be used. Surgical drainage may be necessary and a search for a pyriform sinus fistula should be made, particularly in children with thyroiditis involving the left lobe. Important to differentiate from the acute bacterial infection of acute suppurative thyroiditis (AST) is subacute (granulomatous) thyroiditis (SAT) which is far more common than AST and is characterized by a more protracted course, usually involving the thyroid symmetrically. The gland is also swollen and tender, and the systemic reaction may also be severe, with fever and an elevated erythrocyte sedimentation rate. During the acute phase of the disorder, tests of thyroid function disclose a suppression of TSH, increased serum concentrations of T4, T3, and thyroglobulin while a diminished thyroidal RAIU is observed. The cause of SAT has been established in only a few instances in which a viral infection has been the initiating factor. There may be repeated recurrences of diminishing severity. Usually, but not always, the function of the thyroid is normal after the disease has subsided. Subacute thyroiditis may be treated with rest, non-steroidal anti-inflammatory drugs or aspirin, and thyroid hormone. If the disease is severe and protracted, it is usually necessary to resort to administration of glucocorticoids, but recurrence may follow their withdrawal. It is precisely the observational nature of SAT therapy combined with the use of glucocorticoids which make it so critical to definitively rule out the bacterial etiology of AST in the patient presenting with a painful thyroid.

Riedel's thyroiditis is a chronic sclerosing replacement of the gland that is exceedingly rare. The process extends to adjacent structures, making any surgical intervention very difficult and potentially harmful. The exact cause of Riedel's thyroiditis remains unknown, and no specific treatment is available beyond limited resection of the thyroid gland to relieve the symptoms of tracheal or esophageal compression. The use of anti-inflammatory medical treatments has been

demonstrated to have significant benefits to outcome. Sarcoidosis may involve the thyroid, and amyloid may be deposited in the gland in quantities sufficient to cause goiter. In all of these diseases it may be necessary to give the patient levothyroxine replacement therapy if the function of the gland has been impaired.

CLASSIFICATION

The diagnostic term thyroiditis includes a group of inflammatory or inflammatory-like conditions. The terminology that has been employed is confusing, and no classification is ideal. We prefer the following nomenclature, which takes into account the cause when known.

1. Infectious thyroiditis, also referred to as either acute or chronic, and which in fact may be either, along with the qualifying term suppurative (AST), nonsuppurative, or septic thyroiditis. It includes all forms of infection, other than viral, and is caused by invasion of the thyroid by bacteria, mycobacteria, fungi, protozoa, or flatworms. The disorder is rare.
2. DeQuervain's thyroiditis, commonly known as subacute thyroiditis (SAT) but also termed subacute nonsuppurative thyroiditis, granulomatous, pseudotuberculous, pseudo-giant cell or giant cell thyroiditis, migratory or creeping thyroiditis, and struma granulomatosa. This condition, most likely of viral origin, lasts for a week to a few months, with a tendency to recur. The eponym was selected because of its uncertain cause.
3. Autoimmune thyroiditis, commonly referred to as chronic, Hashimoto's, or lymphocytic thyroiditis and also known as lymphadenoid goiter and struma lymphomatosa. This indolent disease usually persists for years and in the Western world is the principal cause of non-iatrogenic primary hypothyroidism. Nonspecific focal thyroiditis, characterized by local lymphoid cell infiltration without parenchymal changes, may be a variant of the autoimmune disease. The condition is covered in detail in Chapter 8. Another form of thyroiditis, also believed to be of autoimmune cause, has recently been described. It has been variably referred to as painless, silent, occult, subacute, subacute nonsuppurative, and atypical (silent) subacute thyroiditis, as well as hyperthyroiditis, transient thyrotoxicosis with low thyroidal RAIU and lymphocytic thyroiditis with spontaneously resolving hyperthyroidism. There is no agreement on an inclusive name. The features of this disease entity overlap deQuervain's thyroiditis and Hashimoto's thyroiditis. The clinical course, with the exception of a very high erythrocyte sedimentation rate and pain in the thyroid are indistinguishable from deQuervain's thyroiditis. Yet, histologically, the condition cannot be differentiated from a milder form of Hashimoto's disease. This condition often occurs in the postpartum period and is also termed postpartum thyroiditis. All forms of autoimmune thyroiditis are considered in Chapter 8.
4. Riedel's thyroiditis, another disorder of unknown etiology. Synonyms include Riedel's struma, ligneous thyroiditis and invasive fibrous or chronic sclerosing thyroiditis. This condition is characterized by overgrowth of connective tissue which often extends into neighboring structures.
5. Miscellaneous varieties of thyroid inflammation or infiltration including local manifestations of a generalized disease processes. Among these are sarcoid and amyloid involvement of the thyroid. Radiation and direct trauma to the thyroid gland may also cause thyroiditis.

INFECTIOUS THYROIDITIS

The thyroid gland is remarkably resistant to infection. This has been attributed to its high vascularity, lymphatic drainage, the presence of large amounts of iodine in the tissue, the fact that hydrogen peroxide is generated within the gland as a requirement for the synthesis of thyroid hormone and its normal encapsulated position away from external structures. However, in certain situations, particularly in children[1-5], a persistent fistula from the pyriform sinus may make the left lobe of the thyroid particularly susceptible to abscess formation [4, 6-11]. Acute suppurative thyroiditis (AST) is a rare condition, reported to account for 0.1-0.7% of thyroid disease[12] which may result in up to 12% or higher mortality if left untreated[12-14]. Recurrent left-sided thyroid abscess has also been reported due to a fourth branchial arch sinus fistula [15]. A review of 526 cases of congenital fourth branchial arch anomalies [16] noted that they presented with acute suppurative thyroiditis in 45% of cases. In a recent study, 7 out of 48 (15%) of children undergoing pyriform sinus fistula surgery presented with a thyroid abscess[17]. Acute thyroiditis from a periapical abscess of an inferior molar has been reported [18]. Acute thyroiditis can occur in an immuno-compromised state, predisposing them to unusual bacteria such as *Nocardia*[19, 20], *salmonella*[21] and fungi like *Candida*[22-25], *C. Immitis*[26] and *Aspergillus*[27]. Occasionally, acute bacterial suppurative thyroiditis occurs in children receiving cancer chemotherapy [28]. Rarely, infection will occur in a cystic or degenerated nodule[29, 30] or presumed hematogenous spread in the setting of endocarditis[31]. Predisposing factors for the development of acute thyroiditis are outlined in Table 1. As will be discussed, the principal differential diagnosis is generally between acute (AST), meaning infectious, and subacute (SAT), meaning post-viral (non-infectious) inflammation of the gland.

Table 1: Predisposing factors for acute thyroiditis

Pyriform sinus fistula
 Third and fourth Arch abnormalities
 Immunocompromised states
 Rarely, endocarditis, tooth abscess, Fine needle aspiration

Etiology

Virtually any bacterium can infect the thyroid (Table 1). *Streptococcus*, *staphylococcus*, *pneumococcus*, *salmonella*[21, 32-34], *klebsiella*[35], *bacteroides*, *t. pallidum*, *pasteurella* spp [37, 38], *multocida* [38], *porphyromonas*[39], *eikenella* [40-42] and *m. tuberculosis* [43-47] have all been described. The subject has been extensively reviewed [23, 48, 49]. In addition, certain fungi, including *coccidioides immitis*[26], *aspergillus*[27], *actinomyces*[50-52], *blastomycosis*[53], *candida albicans*[22-25], *nocardia* [19, 54-56], *actinobacter baumannii* [14] *cryptococcus* [57] and *pneumocystis* [58] have also been associated with thyroiditis. In the latter cases, the hosts have often been immuno-compromised, either due to malignancy or to AIDS [20, 21, 59, 60]. Rarely acute suppurative thyroiditis is due to thyroid abscess with deep neck infection[61] and fistulous connection [62]. *C. immitis* from infected donor tissue in an immunocompromised host has also been reported[26]. A thyroid abscess due to *clostridium perfringens* has been reported [63] and *clostridium septicum* is almost always associated with carcinoma of the colon [64]. Metastatic breast cancer has been described as presenting clinically with acute thyroiditis [65]. Recently,

the role of diagnostic fine needle thyroid aspiration has been emphasized, firstly as a factor in the cause of acute suppurative thyroiditis with associated thyrotoxicosis in a patient with atopic dermatitis [66], also being causative in a case of secondary infection after aspirating a simple cyst [63], associated with necrosis in a patient with papillary thyroid carcinoma [67] and an intra-thyroidal abscess in a multinodular goiter which grew *E. coli* [68]. Care should be taken when performing FNAC in patients who may be susceptible to tracking of infection into the thyroid. Most commonly, however, especially in children, infection of the thyroid gland is a result of direct extension from an internal fistula from the pyriform sinus [4, 6, 7, 49, 69-71]. This tract is thought to represent the course of migration of the ultimobranchial body from the site of its embryonic origin in the fifth pharyngeal pouch [8]. Careful histopathological studies of these fistulae have demonstrated that they are lined by squamous columnar or ciliated epithelium and occasionally form branches in the thyroid lobe [4, 7]. In addition, occasional cells positive for calcitonin have been found in the fistulae and increased numbers of C-cells were noted in the thyroid lobe at the point of termination of the tract. The predominance of acute thyroiditis in the left lobe of the thyroid gland, particularly in infants and children, is explained by the fact that the right ultimobranchial body is often atrophic and does not develop in the human (as well as in other species such as reptiles). The reason for this phenomenon is not known. Acute thyroiditis may involve a normal gland, arise in a multinodular goiter [72] or even Hashimoto's thyroiditis. At times, no source of infection can be demonstrated. The possibility of a persistent thyroglossal duct should be considered for patients with midline infections [73]. Acute thyroiditis has arisen as the initial presentation of juvenile systemic lupus erythematosus [74] and has also occurred due to septic emboli derived from infective endocarditis [31, 75].

Pathology

Pathological examination reveals characteristic changes of acute inflammation. With bacterial infections, heavy polymorphonuclear and lymphocytic cellular infiltrate is found in the initial phase, often with necrosis and abscess formation. Fibrosis is prominent as healing occurs. In material obtained by fine needle aspiration, the infectious agent may be seen on a gram, acid fast or appropriate fungal stains [6] and grown out in culture for antibiotic sensitivity assessment.

Clinical Manifestations

Although acute thyroiditis is quite rare (about 2 patients per year in a large tertiary care hospital), cases of suppurative thyroiditis are increasing due to the higher incidence of immunocompromised patients. It has been estimated to be much more common in the pediatric age group because of its relationship with pyriform sinus fistulae, where 90% of lesions develop in the left lobe of the thyroid [31] although it is still quite unusual. It has been estimated that about 8% of cases occur in adulthood [31, 76-82]. The dominant clinical symptom is pain in the region of the thyroid gland which may subsequently enlarge and become palpably hot and tender. The patient is unable to extend the neck and often sits with the neck flexed in order to avoid pressure on the thyroid gland. Swallowing is painful. There are usually signs of infection in structures adjacent to the thyroid, local lymphadenopathy as well as temperature elevation and, if bacteremia occurs, chills. Gas formation with suppurative thyroiditis has been noted [83-86].

Symptoms are generally more obvious in children than in adults. Adults may present with a vague slightly painful mass in the thyroid region without fever, which may raise the possibility of a malignancy. Suppurative thyroiditis may even spread to the chest producing necrotizing mediastinitis and pericarditis in the absence of a pyriform sinus fistula [61, 87-89]. It may occur more commonly in the fall and winter following upper respiratory tract infections.

In general, there are no signs or symptoms of hyper- or hypothyroidism. However, exceptions to both have been reported particularly if the thyroiditis is generalized, such as occurs with fungal processes [57] or mycobacterial infections. At times, even in patients with bacterial thyroiditis, destruction of the thyroid gland is sufficient to release thyroid hormone in amounts sufficient to cause symptomatic thyrotoxicosis [38, 43]. The adult thyroid gland contains approximately 600 ug of T4/g [90]. Given a typical 15 to 20 g gland, sufficient hormone can be released to cause transient thyrotoxicosis. Associated thyrotoxicosis has also been reported in children and adults [10, 38, 66, 91], in one series, 12% presented with thyrotoxicosis and 17% were said to be hypothyroid[14]. This variety of thyroid function findings clearly increases the difficulty of differentiating AST from subacute thyroiditis (SAT) as both present with thyroidal pain. Unique presentations of AST have been reported where initial thyrotoxicosis has been followed by hypothyroidism and spontaneous normalization of thyroid function after treatment of the AST[39, 92].

Diagnosis

Pain in the anterior neck will usually lead to a consideration of the possibility of thyroiditis. Since the major differential diagnosis will lie between acute suppurative thyroiditis and subacute thyroiditis, it is critical to compare the history, physical, and particularly laboratory data in these two conditions (see Table 4). In general, the patient with acute thyroiditis appears septic, has greater and more localized pain in the thyroid gland, may have an associated upper respiratory infection, has lymphadenopathy and may be immuno-compromised. Localization of the tenderness to the left lobe should suggest the possibility of an infection as should any erythema or apparent abscess formation. The presence of an elevated white blood count with a shift to the left would argue for infection, however, elevations in sedimentation rate are common in both acute and subacute thyroiditis. As mentioned, patients with bacterial thyroiditis are usually euthyroid but a thyrotoxic presentation has been noted in 8-12%[14, 93] and hypothyroidism was noted in 17% of one series[93]. Thyrotoxicosis is clearly more common, 52% at 7 days and 65% by 30 days of neck pain in patients with subacute thyroiditis [94]. The thyrotoxic presentation therefore makes for a difficult differential diagnostic problem to separate AST from SAT which may have significant impact in the selection of initial therapy.

Table 2 Microbiology of Acute Suppurative Thyroiditis

Usual Organisms
Aerobic:Staphylococcus aureus, Streptococcus pyogenes, Streptococcus epidermidis,

Streptococcus pneumoniae, E Coli[95]
Anaerobic
Clostridium septicum[64]
Gram negative bacilli
Peptostreptococcus spp.
<u>Rare Organisms</u>
Bacterial: Atypical mycobacteria, Clostridium perfringens[63], Eikenella corrodens, Enterobacteriaceae, Haemophilus influenza, Klebsiella spp., Mycobacterium tuberculosis, Porphyromonas[39], Salmonella spp., streptococcus viridans, Treponema pallidum, Echinococcus spp.
Fungal: Aspergillus spp., Blastomycosis, Candida spp., Coccidioides immitis, Pneumocystis jiroveci
Parasitic: Trypanosoma[49]

Depending on the age and clinical circumstances, one may wish to proceed with invasive or non-invasive studies. Discriminating tests for recognizing a difference between AST and SAT have been considered a radio-nuclide uptake or scan usually showing a very low value in subacute thyroiditis with a normal value found in the patient with very localized mild bacterial thyroiditis [49]. More frequently however both conditions are associated with a low 123-I uptake at initial presentation[20, 92, 96, 97] limiting the power of nuclear scanning to effectively differentiated these two conditions.

A thyroid ultrasound may be done but characteristic findings vary depending on the phase of AST during which the patient is observed. In the early inflammatory phase of AST, when obvious abscess formation is not evident, the ultrasound may show a localized hypoechoic process with an obscure border and effacement between the thyroid and surrounding perithyroidal tissues[98]. During the acute inflammatory stage of AST, clear cut abscess formation is noted in the affected thyroidal tissue[98]. Perithyroidal unifocal hypoechoic space and effacement of the plane between the thyroid and perithyroid tissues have been noted to be specific signs of AST[98]. Alternatively, the application of sonoelastography may reveal very stiff lesions corresponding to the areas of the thyroid which are especially painful[99] during acute phases of the AST episode which soften significantly as the patient responds to treatment[99]. As the AST resolves with appropriate treatment, ultrasound images may demonstrate deformity of the gland characterized by atrophy of the affected lobe, air pockets in the thyroidal tissue and scarring of the perithyroidal tissues[98].

A CT scan may be useful in identifying the location of the abscess, but this has been said to be required only in unusual situations [100]. The CT findings also vary with the stage of AST. In the early inflammatory stage, nonspecific low density areas in the swollen thyroid along with potential tracheal displacement may be seen[98]. In the acute inflammatory stage, a CT can also demonstrate edema of the ipsilateral hypopharynx, and abscess formation. In the late inflammatory stage, deformity of the thyroid, atrophy of the affected lobe and scarring of the perithyroidal tissues may be observed[98]. Recent reviews indicate a significant role for CT in the initial evaluation of those with AST[12, 98]. As outlined above, during the earliest stages of AST both CT and ultrasound findings may fail to effectively differentiate between AST and SAT. In this circumstance the use of a fine needle aspiration (FNA) has been demonstrated to be very useful as outlined below. Gallium scans are sometimes performed in the course of an evaluation for a fever of unknown origin. Localization of gallium to the thyroid gland would be a very useful finding confirming thyroid inflammation as the source of the problem but the differential of gallium positive thyroid tissue will also include the presence of Riedel's thyroiditis[101].

If an infectious process is identified, particularly of the left lobe of a younger individual, then a barium swallow should be performed with attention to the possibility of a fistulous tract located on the left side between the pyriform sinus and the thyroid gland. The barium swallow has very good sensitivity in detecting the presence of the fistular tracts as 89-97% of those examined in early and acute stages of AST were confirmed with this technique[98]. Other methods of documenting the presence of a fistula are also utilized. On follow up ultrasound an 'emerging echogenic tract sign' suggests an associated pyriform sinus thyroid fistula [102]. During a CT scan procedure the patient can be asked to blow into a syringe, the so called "trumpet maneuver", which may help to identify a pyriform sinus fistula [103], a recent series suggests that timing may influence the ability of this maneuver to demonstrate the presence of the fistula as only 20% of those examined in the acute inflammatory phase revealed a fistula while 54% of those evaluated in the late inflammatory phase had a fistula documented[98] with the "trumpet maneuver". A 'light guided procedure' to visualize the tract may also help [104]. Transnasal flexible fiberoptic laryngoscopy has become increasingly utilized to identify the presence of the fistular tract[12]. This approach has been estimated to have similar sensitivity of documenting the tracts as barium swallow and CT methods[105-107] and can also be utilized for the instillation of chemo-cauterizing agents at an appropriate time after the resolution of the acute infection[93, 105, 107, 108].

Occasionally, pain from an infectious process elsewhere in the neck will present as anterior neck tenderness. For example, a retropharyngeal abscess may present with typical symptoms of acute thyroiditis. The thyroid gland, however, will have a normal uptake, be normal on scan, and only on CT scan will the retropharyngeal abscess be recognized. The tendency for the pain of thyroid inflammation to be referred to the throat or ears should be kept in mind, although recognition of the anatomic source of the problem is usually not such a difficult issue in patients with acute thyroiditis due to their localized symptoms. While patients with tuberculosis or parasitic infections tend to have a more indolent course, these infections can present with acute symptoms and this possibility should be considered if the epidemiology is consistent. For example, thyroidal echinococcosis occurs in countries in which this parasite is endemic [109]. Trypanosomiasis of the thyroid has also been reported [49].

A fine needle aspiration (FNA) performed in either of the acute phases of AST is important as the FNA has a superior ability to differentiate the patient with AST from those with subacute thyroiditis by cytologic criteria and also provides appropriate bacteriologic specificity allowing more accurate antibiotic selection[12] for the patient documented to have AST. In addition, transcutaneous aspiration of the infectious material can be performed to relieve pressure on a displaced trachea in patients with a compromised airway[12]. Finally FNA may be seen as the most accurate means of differential diagnosis[110] when a thyrotoxic presentation is encountered. Establishing a firm diagnosis of AST allows appropriate antibiotic therapy to be prescribed when a trial of glucocorticoids for empirically assumed SAT might result in both delay in diagnosis as well as initiation of a potentially wrong therapy[39].

Treatment

A recent clinical review [12] concluded that there may be a trend toward less invasive management during active inflammation and infection. Despite lack of randomized controlled trials algorithms for acute and long term management were suggested by these authors. Miyauchi [96], who has a very large experience of the condition, has cautioned that consideration of the basic anomaly predisposing the patient to thyroid gland infection must be duly considered. The diagnosis and choice of antibiotic therapy are often aided by microscopic examination and appropriate staining of a fine needle aspirate. The procedure is best done under ultrasound guidance so that the source of the specimen is identified. It may also serve as a mechanism for drainage of an abscess and can be repeated to facilitate healing. Some abscesses will require surgical exploration and drainage. The choice of therapy will also depend on the immune status of the patient. Systemic antibiotics are required for severe infections. *Candida albicans* thyroiditis can be treated with amphotericin B and 5 fluconazole 100 mg daily. The proper treatment of an acute thyroiditis in children generally requires the surgical removal of the fistula [4, 6, 7], although surgical treatment should be delayed until the inflammatory process is resolved [111, 112]. Combining this with partial thyroidectomy may further decrease the recurrence rate [5, 16]. In addition, formal lobectomy may be the safer option as it provides an adequate identification of the recurrent laryngeal nerve in the re-operative field[113]. Alternatively, fistula tract ablation can be achieved either by surgical resection which has been associated with recurrence free survival [98], or less invasively obliterated with the instillation of a chemo-cauterizing agent which has also been demonstrated to result in satisfactory outcomes [98, 105, 107, 108]. Newer, minimally invasive transoral video-laryngoscopic surgery (TOVS)[114] and endoscopy assisted surgery[115] have been reported to be safe and reliable methods of pyriform sinus fistula treatment.

Prognosis

The disease may occasionally prove fatal[89]. In some patients with thyroiditis, the destruction may be sufficiently severe that permanent hypothyroidism results [72]. Thus, patients with a particularly diffuse thyroiditis should have follow-up thyroid function studies performed to

determine that this has not occurred. Surgical removal of a fistula or branchial pouch sinus [111, 112] is required to prevent recurrence.

SUBACUTE THYROIDITIS

Case Illustration

J.G., a 56-year old woman presented to her primary care physician in January, with 4 weeks of low anterior neck pain and 2 days of fatigue, chills and shivers. She was prescribed a course of antibiotics with no relief. A CT scan of the neck was done which showed mild diffuse thyroid enlargement, multiple nodules and area of hypo-attenuation on the right lobe with no evidence of abscess formation. She was referred to Endocrinology for further evaluation. Upon further questioning, she admitted to having intermittent fever, nervousness, slight difficulty during swallowing, nearly 5 pound weight loss but no changes in her appetite or bowel habits. A family history of thyroid disease was not elicited. She has been taking Naproxen 200 mg four times a day and a full dose aspirin with minimal relief.

On physical examination she appeared to be in pain, BP was 144/88, and pulse 108/min and regular. Clinically, she appeared to be euthyroid. The thyroid gland was estimated to be 40 grams in weight and was tender, firm, and slightly irregular. The remainder of the examination was non-contributory.

Laboratory data included an erythrocyte sedimentation rate of 58 mm/min, FT4 of 2.7 ng/dl (normal, 0.76 to 1.46 ng/dl), FT3 5.8 pg/ml (2.3 to 4.2 pg/mL) and a negative Thyroid Stimulating Immunoglobulin. CRP was 31.3 mg/L (normal 0.0-8.0 mg/L). RAI uptake and scan showed 1% uptake.

Subacute thyroiditis (SAT) sometimes referred to as granulomatous or De Quervain's thyroiditis is a spontaneously remitting inflammatory condition of the thyroid gland that may last for weeks to several months [49, 116, 117]. It has a tendency to recur. The gland is typically involved as a whole, and thyroidal RAIU is much depressed. Transient hyperthyroxinemia, elevation of the serum thyroglobulin concentration and the erythrocyte sedimentation rate and sometimes the WBC during the early acute phase are characteristic if not pathognomic.

Etiology

A cause can rarely be established. A tendency for the disease to follow upper respiratory tract infections or sore throats has suggested a viral infection. Earlier suggestions that the disease may represent a bacterial infection have been disproven. An autoimmune reaction is also unlikely. The development during the illness of cell-mediated immunity against various thyroid cell particulate fractions or crude antigens appears to be related to the release of these materials during tissue destruction[118, 119].

Although the search for a viral cause has usually been unrewarding, a few cases seem to be due to the virus that causes mumps[116, 120] The disease has occurred in epidemic form. High titers of mumps antibodies have been found in some patients with subacute thyroiditis, and occasionally parotitis or orchitis is associated with thyroiditis. The mumps virus has been

cultured directly from thyroid tissue involved by subacute thyroiditis. Although the mumps virus seems to be one discrete etiologic factor, the disease has been reported in association with other viral conditions including measles, influenza, H1N1 influenza[121] adenovirus infection, infectious mononucleosis[122], myocarditis, HIV[123], cat scratch fever, and coxsackie virus [124], most recently SAT has been reported following hand-foot-mouth disease due to coxsackie B4[125] and scrub typhus infection[97]. Two comprehensive studies[126, 127] failed to find evidence of enteroviruses in 27 patients and Epstein-Barr virus or cytomegalovirus in 10 patients, respectively but a single case report has implicated EB virus in a case of subacute thyroiditis with typical clinical features[128] and cytomegalovirus has now been reported in an infant[129].

Numerous attempts to culture viruses from cases not associated with mumps have failed. Virus-like particles have been demonstrated in the follicular epithelium of a single patient suffering from subacute thyroiditis[124]. However, viral antibody titers to common respiratory tract viruses are often elevated in these patients. Since the titers fall promptly, and multiple viral antibodies may appear in the same patient, the elevation probably is an anamnestic response to the inflammatory condition. It is likely that the thyroid gland could respond with thyroiditis after invasion by a variety of different viruses but no single agent is likely to be causative[130].

Histo-compatibility studies show that 72% of patients with subacute thyroiditis manifest HLA-BW35[131]. Familial occurrence of subacute thyroiditis associated with HLA-B35 has been reported[132-135]. Thus, the susceptibility to subacute thyroiditis is genetically influenced and it has also been suggested that subacute thyroiditis might occur by transmission of viral infection in genetically predisposed individuals[129]. A reported association between subacute thyroiditis and acute febrile neutrophilic dermatosis (Sweet's syndrome)[136, 137], may imply a common role for cytokines in both these conditions.

New treatments, particularly those in which there is manipulation of the immune system, have led to the development of subacute thyroiditis[138]. Infusion of interleukin 2 caused hyperthyroxinemia with a low radioiodine uptake in six patients who received this in combination with tumor necrosis factor (TNF) α or γ interferon[139]. The patients proceeded to pass through the pattern of hyperthyroidism and transient hypothyroidism, with a re-establishment of normal thyroid function typical of the patient with autoimmune painless thyroiditis. However, none of the patients had detectable antithyroid antibodies. This condition is thus intermediate between subacute lymphocytic (painless) thyroiditis (Chapter 13) and subacute thyroiditis which is typically painful. Similarly, painless thyroiditis has been reported during treatment with anti-programmed cell death 1 (PD-1) monoclonal antibodies for metastatic malignancies. Of the ten cases reported two of them had no evidence of anti-thyroglobulin antibodies and anti-TPO antibodies[140]. Patients have developed subacute thyroiditis after influenza vaccination[141, 142] suggesting immune alteration as a contributory factor. In patients with chronic hepatitis C studies following interferon therapy (IFN) showed that a minority (15%) developed a destructive thyroiditis while others had a mild elevation of TSH[139, 143]. IFN can exacerbate previous thyroid autoimmunity and cause destructive thyroidal changes de novo. Subacute thyroiditis has also been noted in patients treated with combination therapy of IFN plus ribavirin for this

disease[144, 145] as well as during treatment of hepatitis B with Interferon[146]. Peginterferon alpha-2a has also been reported to cause subacute thyroiditis[147] and the condition is seen in Takayasu's arteritis suggesting an immune abnormality[148]. On the other hand, subacute thyroiditis has been reported in patients receiving long term immunosuppressive therapy suggesting a minimal role for autoimmunity in the condition[149, 150]. A phase 2 trial conducted on Alemtuzumab, a monoclonal anti-CD52 antibody for relapsing and remitting type of multiple sclerosis found that 34% of the subjects had some thyroid dysfunction and 4% of them had subacute thyroiditis[151]. Other reports of subacute thyroiditis for example with renal cell carcinoma[152], following the administration of cardiac catheterization dye[153], after gastric bypass[154] or after ginger ingestion[155] do not clearly contribute to an enhanced understanding of its etiology.

Pathology

The thyroid gland may be adherent to its capsule or to the strap muscles but it can usually be dissected free, a feature distinguishing subacute thyroiditis from Riedel's thyroiditis. The involved tissue appears yellowish or white and is more firm than normal. The gland is enlarged, and the enlargement is usually bilateral and uniform, but it may be asymmetrical, with predominant involvement of one lobe. Although the lesion may extend to the capsular surface, it can also be confined to the thyroid parenchyma and merely be palpable as a suspiciously hard area.

The macroscopic pathologic picture of subacute thyroiditis frequently bears a striking resemblance to cancer. The lesion is firm to dense in consistency, pale white in color, and has poorly defined margins that encroach irregularly on the adjacent normal thyroid. Microscopically, one sees a mixture of subacute, chronic, and granulomatous inflammatory changes associated with zones of parenchymal destruction and scar tissue. Early infiltration with polymorphonuclear leukocytes is replaced by lymphocytes and macrophages. The normal follicles may be largely replaced by an inflammatory reaction, but a few small follicles containing colloid remain (Fig. 1, below). Three dimensional cytomorphological analysis of fine needle aspiration biopsy samples from patients with subacute thyroiditis examined with scanning and transmission electron microscopy has shown a loss of a uniform, honeycomb cellular arrangement; variation in size and decrease or shortening of microvilli in follicular cells together with the appearance of round or ovoid giant cells[156]. The most distinctive feature is the granuloma, consisting of giant cells clustered about foci of degenerating thyroid follicles (Fig. 1). The early literature contains accounts of tuberculous thyroiditis, a diagnosis largely based on the granulomatous tissue reaction, from which the descriptive but unfortunate term pseudotuberculous thyroiditis arose[157]. Data on the mechanism of inflammation and the pathogenesis of subacute thyroiditis at the cellular level are sparse. However, a study of apoptosis and expression of Bcl-2 family proteins in 11 patients with SAT suggests that apoptotic mechanisms may be involved in the development of SAT[158]. Growth factor rich monocytes/macrophages (containing VEGF, beta FGF, PDGF and TGF beta 1) are involved in the granulomatous stage[159]. EGF is important in the regenerative stage as it has mitogenic effects on the thyrocyte. VEGF and beta FGF contribute to the angiogenesis at both these stages of the disease. Factors influencing the

severity of the acute phase response during the course of SAT include serum interleukin -1 receptor antagonist which may have a significant anti-inflammatory role[160]; also, a decrease in TNF alpha results in earlier resolution of experimentally induced granulomatous thyroiditis[161] TNF- related apoptosis-inducing ligand (TRAIL) has been shown to promote resolution of granulomatous autoimmune thyroiditis in animal models[162].

Mast cells play an important part in the repair process of thyroid tissue affected by the disease via production of growth factors and biomolecules which modulate thyroid folliculogenesis and angiogenesis[163].

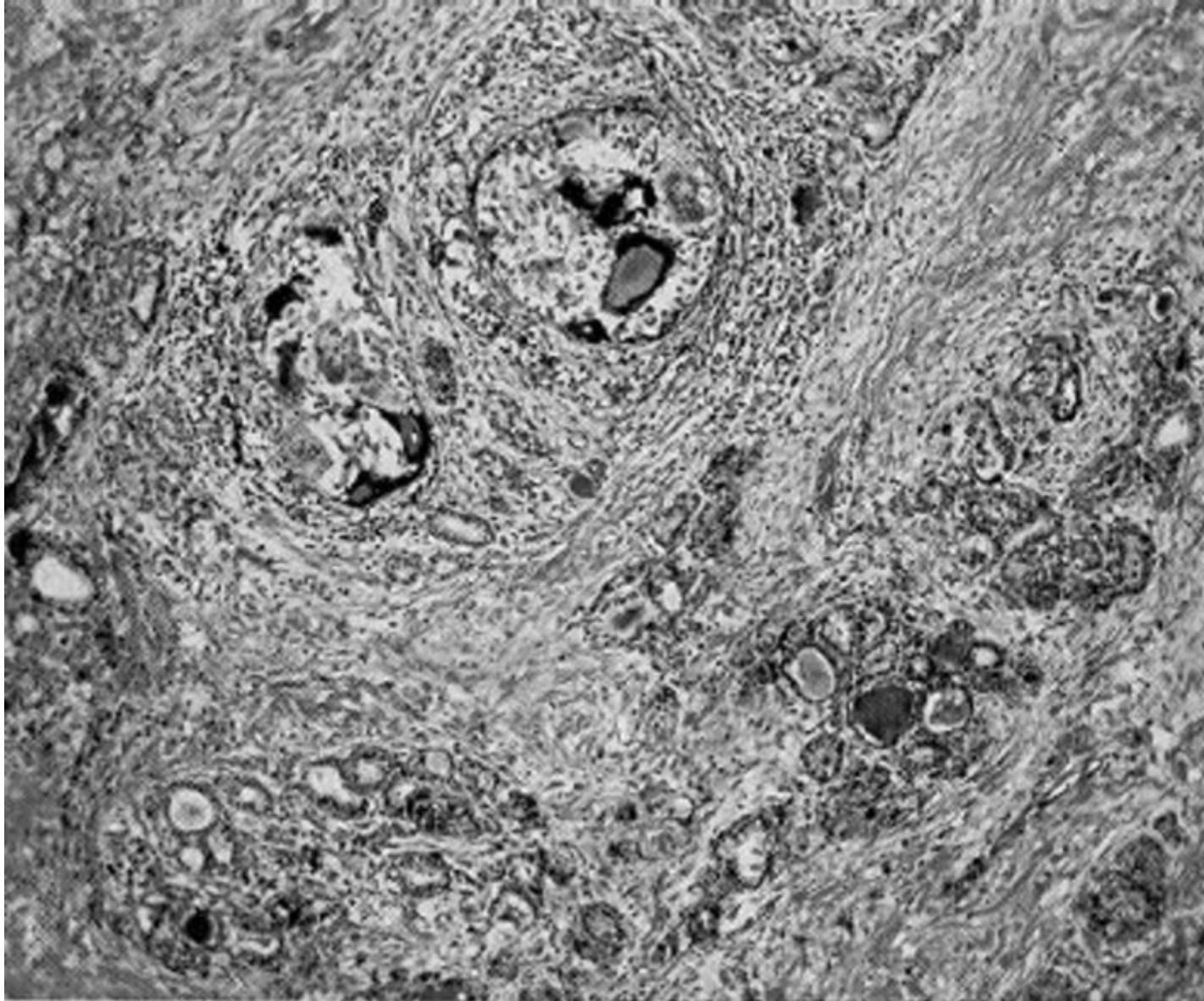


Figure 1. Subacute thyroiditis. Note the discrete granulomas, with giant cells, and the diffuse fibrosis (85 X).

INCIDENCE and PREVALENCE

Subacute thyroiditis is encountered in up to 5% of patients with thyroid illness[164]. Woolner et al.[157] collected 162 cases diagnosed on clinical grounds at the Mayo Clinic over a 5-year period; during the same time, 1,250 patients with Graves' disease were seen. Thus, the disease had approximately one-eighth the incidence of Graves' disease in this clinic population. During an evaluation of subtypes of hypothyroidism over a 4 year period in Denmark an incidence of subacute thyroiditis of 1.8% was found in a cohort of 685 patients with hypothyroidism[165]. Although the disease has been described at all ages, it is rare in children[71, 117]. Female patients have outnumbered male patients in a ratio of 1.9-6:1, with a preponderance of cases in the third to fifth decades[48, 116, 157, 166, 167] and it has been noted as a rare cause of hyperthyroidism in pregnancy[168, 169]. In 160 patients studied during 37 years at the Mayo Clinic an age and sex adjusted incidence of 4.9 cases/100,000/year was noted[166].

Clinical Manifestations

Characteristically, the patient has severe pain and extreme tenderness in the thyroid region. A small number of patients has been noted to present with painless or minimally painful subacute thyroiditis following viral symptomatology[170]. These may be regarded as atypical subacute thyroiditis patients but their natural history of the disease is not known. Subacute thyroiditis has been reported to occur during the first trimester of pregnancy[168]. When the symptom is difficulty in swallowing, the disorder may be initially mistaken for pharyngitis. Transient vocal cord paresis may occur[171]. At times, the pain begins in one pole and then spreads rapidly to involve the rest of the gland ("creeping thyroiditis"). Pain may radiate to the jaw or the ears. Malaise, fatigue, myalgia and arthralgia are common. A mild to moderate fever is expected, and at times a high, swinging fever with temperatures above 104°F (40.0°C). The disease may reach its peak within 3 to 4 days and subside and disappear within a week, but more typically, a gradual onset extends over 1 to 2 weeks and continues with a fluctuating intensity for 3 to 6 weeks. Several recurrences of diminishing intensity extending over many months may be the unhappy fate of the patient.

The thyroid gland is typically enlarged two or three times the normal size or larger and is tender to palpation, sometimes exquisitely so. It is smooth and firm. Occasionally the condition may be confined to one lobe[172, 173]. Approximately one-half of the patients present during the first weeks of the illness, with symptoms of thyrotoxicosis, including nervousness, heat intolerance, palpitations - including ventricular tachycardia[174], tremulousness, and increased sweating. These symptoms are caused by excessive release of preformed thyroid hormone from the thyroid gland during the acute phase of the inflammatory process. At least 2 cases of thyroid storm due to subacute thyroiditis have been described[175, 176] and adverse cardiac outcomes have been reported even in individuals without preexisting cardiac history or lesions[177]. As the disease process subsides, transient hypothyroidism occurs in about one-quarter of the patients. Ultimately thyroid function returns to normal and permanent hypothyroidism occurs in less than 10 percent of the cases[48, 49, 116]. Occasionally the condition may be painless and present as fever of unknown origin[178] or associated with other findings and mimicking conditions such as temporal arteritis[179]. Some clinical and laboratory features recorded in 2

series of SAT are shown in Table 2[94, 180]. Liver function test abnormalities are found in half the patients and return to normal in a few months[181].

TABLE 2- Clinical Features of Subacute Thyroiditis

Feature	Japan	Israel
Number	852	56
Females(%)	87	70
Season	summer-autumn	no effect
Recurrence	1.6%	9%
Temp >38 ⁰	28%	--
Thyrotoxic symptoms	60%	--
Hypothyroid phase	--	55%
Labs-peak levels	1 week	--
ATA	--	25%
US:		
Bilateral hypoechogenicity	50%	70%
Nodules	--	70%
Disease duration (days)	--	77
ATA: Antithyroid antibodies. US: Thyroid ultrasound. --: no data		
Data derived from refs [94, 180].		

Diagnosis

Table 3 provides a comparison between the clinical and laboratory findings of patients with subacute and acute thyroiditis[49, 182-187]. Laboratory examination may disclose a moderate leukocytosis. A curious and striking elevation of the erythrocyte sedimentation rate, at times above 100 mm/hr, or an elevated level of serum C-reactive protein[188] is a useful diagnostic clue. Recently the identification of CRP in salivary samples provides a convenient source for documenting the presence of abnormal levels in those with SAT[189]. Short of a tissue diagnosis, most helpful is the characteristic combination of elevated erythrocyte sedimentation rate, high serum T4, T3, and TG concentrations in the presence of low thyroidal RAIU, TSH, and an absent or low titer of circulating TPO and TG antibodies. While the estimation of thyrotropin receptor antibodies (TRAb) in a thyrotoxic patient may be clinically useful in identifying Graves' disease there have been reports of positive TRAb in patients with subacute

thyroiditis although the frequency of this finding is low[190-193]. Mild anemia and hyperglobulinemia may be present.

The value of a 99m-Tc-pertechnetate scintigraphy as a marker of disease activity and severity has been described[194]. Pertechnetate scanning, although inexpensive and convenient, typically reveals little to no uptake and thus no visualization of the SAT process[194, 195], a finding consistently reported in the literature[121, 125, 177, 196-198]. Further imaging studies have shown diffuse increased uptake of Tc-99m sestamibi[195] and Tc-99m tetrofosmin[194] in the thyroid region of patients in the acute phase (thyrotoxic) of subacute thyroiditis suggesting an ability of both agents to detect the inflammatory process associated with the disease[194, 195]. In the same patients color Doppler ultrasonography showed an absence of vascularization in the acute phase and its use in the differential diagnosis of unclear cases has been emphasized[199, 200]. Standard ultrasonographic images are characterized by hypoechoic appearance of the affected tissue the volume of which correlates with the severity of clinical discomfort[201, 202]. The application of newer technologies such as sonoelastography has the capacity to demonstrate markedly decreased elasticity (enhanced stiffness) in SAT lesions[99]. Subacute thyroiditis may obscure the coexistence of papillary carcinoma in cases presenting with ultrasonographically diffuse hypoechoic areas[203]. Subacute thyroiditis with thyrotoxicosis may also be distinguished from Graves' hyperthyroidism by using T1- and T2- diffusion weighted magnetic resonance imaging[204] and as an intense area of uptake on (18) F-FDG PET/CT[198, 205] although these investigation may not be available or even desirable in all centers. Fine needle aspiration biopsy is often diagnostic although patients are often alarmed at the prospect of this test due to the pain in the thyroid. However FNA may be helpful in ruling out malignancy[206] and the infection associated with localized, painful lesions of AST (see above).

Table 3. Features Useful in Differentiating Acute Suppurative Thyroiditis and Subacute Thyroiditis

	Characteristic	Acute Thyroiditis	Subacute Thyroiditis
History	Preceding upper respiratory infection	88%	17%
	Fever	100%	54%
	Symptoms of thyrotoxicosis	Uncommon	47%
	Sore throat	90%	36%
Physical Examination of the thyroid	Painful thyroid swelling	100%	77%
	Left side affected	85+%	not specific
	Migrating thyroid tenderness	Possible	27%
	Erythema of overlying skin	83%	not usually
Laboratory	Elevated white blood cell count	57%	25-50%
	Erythrocyte sedimentation rate	100%	85%

	Characteristic	Acute Thyroiditis	Subacute Thyroiditis
	(>30mm/hr)		
	Abnormal thyroid hormone levels(elevated or depressed)	5-10%	60%
	Alkaline phosphatase, transaminases increased	Rare	common
Needle Aspiration	Purulent, bacteria or fungi present	~100%	0
	Lymphocytes, macrophages, some polys, giant cells	0	~100%
Radiological	¹²³ I uptake low	Common	~100%
	Abnormal thyroid scan	92%	Non-visualized
	Thyroid scan or ultrasound helpful in diagnosis	75%	Non-specific
	Gallium scan positive	~100%	~100%
	¹⁸ F-FDG-PET	Positive	Positive
	Barium swallow showing fistula	Common	0
	CT scan useful	Varies	not indicated
Clinical Course	Clinical response to glucocorticoid treatment	Transient	100%
	Incision and drainage required	85%	No
	Recurrence following operative drainage	16%	No
	Pyriiform sinus fistula discovered	96%	No
Modified from Szabo and Allen [49], see also Shabb & Solti [206]			

If subacute thyroiditis affects only one part of the thyroid gland, the serum T4 concentration and thyroidal RAIU may be entirely normal. A thyroid scan done with either radioactive iodine or ^{99m}Tc-pertchnetate will demonstrate failure of the involved areas of the gland to concentrate the tracer. When the thyroid is diffusely involved, which is more typical, a dramatic disturbance in iodine metabolism is observed.

During the initial phase of the disease, the RAIU is depressed or entirely absent and the concentrations of serum T4 and T3 are often elevated. Due to the concomitant release of non-hydrolyzed iodoproteins from the inflamed tissue, the serum thyroglobulin level is also high. During this phase the serum TSH level is low. Analysis of the TSH suppression seen in thyrotoxic patients indicates that patients with SAT may demonstrate suppressed but detectable levels of TSH while those with Graves' disease or silent thyroiditis have undetectable TSH values[207]. As those with SAT are evaluated sooner in the course of thyrotoxicosis due to the pain of the condition, the duration of the thyrotoxicosis is less, leading to proportionally less TSH

suppression. This finding has been proposed to be useful in the differential diagnosis of these thyrotoxic states[207]. The TSH response to TRH is suppressed[183] due to the high levels of circulating thyroid hormone. Iodide that is collected and metabolized by the gland is rapidly secreted because of the decreased ability to store colloid[185]. At this time, the involved tissue shows decreased but not necessarily depleted stores of iodine, as determined by x-ray fluorescence[182, 185], a study which is not readily available in most clinical settings in the USA. Administration of TSH will fail to produce a normal increase in RAIU. Evidently, thyroid cell damage reduces the ability of the gland to respond to TSH. As the process subsides, the serum T4, T3, and TG levels decline, but the serum TSH level remains suppressed. The normal concentrations of SHBG sometimes observed in the thyrotoxic phase probably reflects the short duration of exposure to increased thyroid hormone[208]. Later, during the recovery phase, the RAIU becomes elevated with the resumption of the ability of the thyroid gland to concentrate iodide. The serum T4 concentration may fall below normal; the TSH level may become elevated. Usually after several weeks or months, all the parameters of thyroid function return to normal (Fig. 2). Restoration of iodine stores appears to be much slower and may take more than a year after the complete clinical remission[182, 185]. In about 2% of patients subacute thyroiditis may trigger auto-reactive B cells to produce TSH receptor antibodies, resulting in TSH antibody associated thyroid dysfunction in some patients[191]. This finding may be a potential explanation of the apparent occurrence of Graves' disease following an episode of SAT[209].

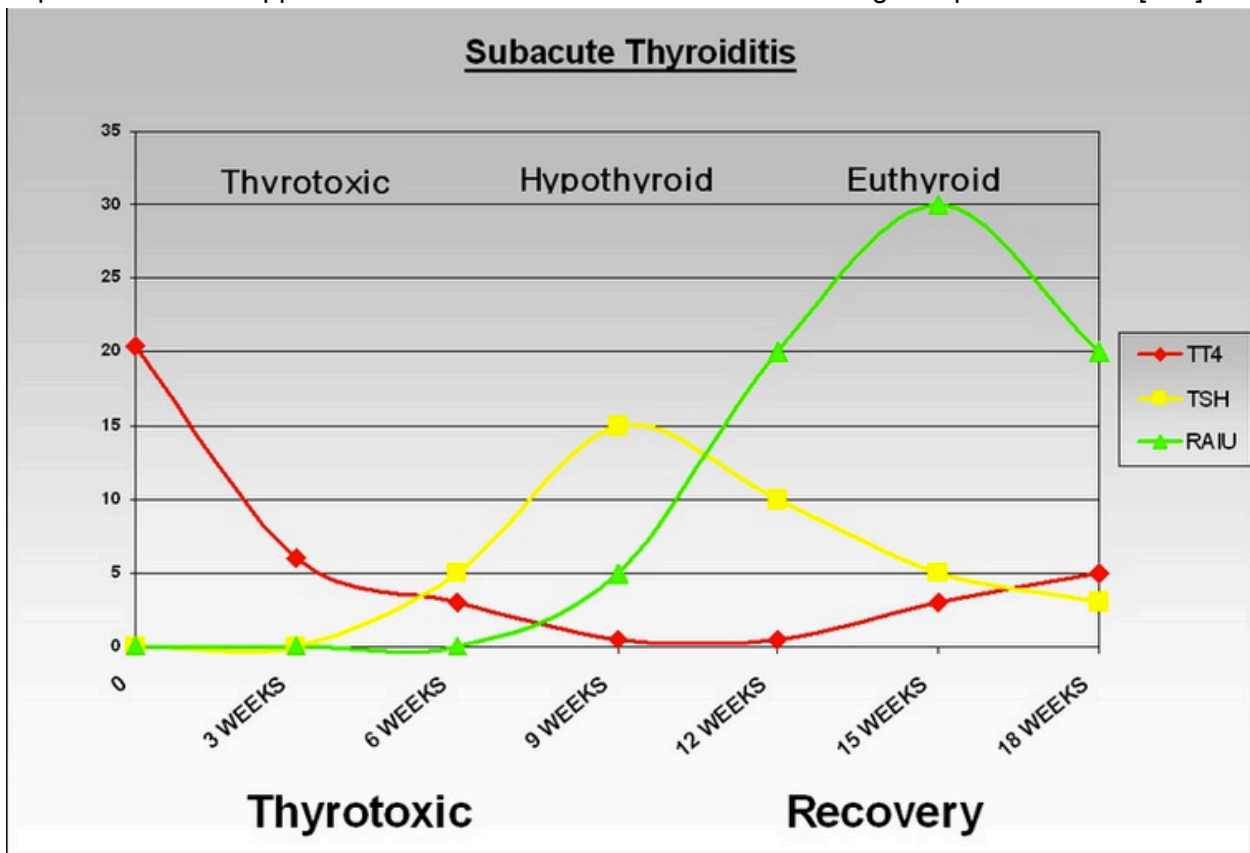


Figure 2. Thyroid function during the course of deQuervain's (subacute) thyroiditis. During the thyrotoxic phase, Total T4 is high, and TSH is suppressed. Later during the period of

hypothyroidism there is gradual increase in TSH until TSH is normalized. Radioactive Iodine uptake which is initially suppressed improves during recovery phase.

Differential Diagnosis

The patient presenting with painful neck symptoms is frequently empirically treated with antibiotics with minimal evaluation in general practice only later to be found to have thyroid related disease[197]. With an acutely enlarged, tender thyroid, an RAIU near zero, and elevated serum T4, T3, thyroglobulin concentrations and ESR, the diagnosis is almost certain. Circulating thyroid autoantibodies are absent or the titer is low. Among the diagnostic alternatives, the uncommon presentation of thyrotoxicosis in infectious thyroiditis must be considered[39] and the possibility of invading bacteria excluded (see Table 2). Rarely a fever of unknown origin may suggest temporal arteritis but is actually due to subacute thyroiditis[179]. Additionally, because of the radiation of painful thyroid into the jaw area the presence of dental pain may be confused with SAT[210]. The thyroid in Hashimoto's thyroiditis (HT) may be slightly tender and painful, but this event is rare, and the typical disturbances in iodine metabolism and erythrocyte sedimentation rate are rarely found. Markers of inflammation such as CRP as measured in the saliva are normal in HT when compared to controls but are grossly elevated in the patient with SAT[189].

Standard thyroid ultrasonography may appear similar with hypoechoic tissue in both HT and SAT but by sonoelastography the SAT gland is profoundly stiffer than HT tissue which is somewhat stiffer than normal controls[99]. The radio nuclide thyroid uptake and scanning in HT is variable with elevated, depressed or normal results reported. ¹⁸F-FDG-PET in Hashimoto's on the other hand is similar to that seen in SAT with usually very positive uptake reported[198, 211, 212]. Magnetic resonance imaging does not differentiate between HT and SAT[204] and is therefore, like ¹²³I and PET scanning, of little value in separating the patient with painful Hashimoto's from the SAT patient.

Hemorrhage into a cyst in a nodular thyroid gland may be confused with subacute thyroiditis although the condition may be associated with an autonomously functioning nodule[213]. Hemorrhage is usually more sudden and transient, a fluctuant mass may be found in the involved region, and the erythrocyte sedimentation rate is normal. Occasionally, subacute thyroiditis mimics hyperthyroidism in a patient whose RAIU is suppressed by the administration of exogenous iodine. This event occurs particularly in transient thyrotoxicosis induced by iodine[186]. The sudden onset of subacute thyroiditis, the presence of toxic symptoms without the typical signs of long-term hyperthyroidism, the tender gland, the constitutional symptoms, and the high erythrocyte sedimentation rate are helpful in making the differentiation. In some instances, measurement of antibodies and thyroid-stimulating immunoglobulins, and observation of the course of the illness may be required to confirm the diagnosis.

The single disease entity that is probably most difficult to differentiate from subacute thyroiditis is a variant of lymphocytic thyroiditis[187]. This condition is unrelated to iodine ingestion and most likely is a variant of autoimmune thyroiditis. The patient presents with goiter, mild

thyrotoxicosis, and a low RAIU. The course of the disease is indistinguishable from that of subacute thyroiditis and proceeds from a thyrotoxic phase through a hypothyroid phase to spontaneous remission with normalization of thyroid function. The goiter is however, typically painless and there are no associated systemic symptoms. This condition has been formerly confused with subacute (de Quervain's) thyroiditis, which likely has led to the descriptive terms of silent, painless, or atypical subacute thyroiditis to refer to this entity. The most helpful distinguishing features, short of histologic examination of biopsy material, are the absence of pain and a normal erythrocyte sedimentation rate. (See also Chapter 13.)

Localized subacute thyroiditis, with induration, mild tenderness, and depressed iodine binding visualized on scan, can clearly be very suggestive of acute suppurative thyroiditis or even thyroid cancer. One series indicated a surprisingly high frequency of focal involvement observed among those with SAT[200]. Indeed this differential is quite difficult when incidentally discovered lesions are evaluated. Thyroid lesions incidentally identified by 18F-FDG-PET/CT are said to have malignant potential in 14-63% of lesions identified[214, 215]. Among the other diagnostic findings reported to account for such FDG-PET incidentalomas is focal SAT[205]. Usually the degree of pain and tenderness, elevated erythrocyte sedimentation rate, leukocytosis, and remission or spread to other parts of the gland make clinical differentiation possible. Traditional ultrasonography may reveal localized hypoechoic area in the thyroid and gray-scale and color Doppler sonography may be helpful in this situation[199, 216]. Sonoelastography of these nodular lesions yields abnormally inelastic results in both SAT as well as thyroid cancer[217]. Occasionally, magnetic resonance imaging[204], where the image of SAT is characterized by low intensity, may assist the clinician in differential of these nodular lesions. The hypoechoic area can reflect the degree of inflammation and thyroid hormone levels[201]. However, a fine needle aspiration is required for a definitive differentiation between these two processes [213] as well as the other entities noted above[110].

Therapy

In some patients with SAT, no treatment is required. However, for many, some form of analgesic therapy is required to treat the symptoms of the disease until it resolves. At times, this relief of symptoms can be achieved with non-steroidal anti-inflammatory agents or aspirin. However, if this fails, as it often does when the symptoms are severe, and after acute suppurative thyroiditis had been definitively ruled out as outlined above, prednisone administration should be employed[48, 116]. Large doses promptly relieve the symptoms through non-specific anti-inflammatory effects. Treatment is generally begun with a single daily dose of 40 mg prednisone. However, a dose as low as 15 mg of Prednisolone has been shown to be as effective[218] and further studies should be conducted to determine the lowest effective doses. After one week of this treatment, the dosage is tapered over a period of 6 weeks or so. The relief of the tenderness in the neck is so dramatic as to be virtually diagnostic of subacute thyroiditis. As the dose is tapered, most patients have no recrudescence of symptoms, but occasionally this does occur and the dose must be increased again. A newer therapeutic approach with local injection of lidocaine and dexamethasone through an insulin syringe has been reported to alleviate symptoms earlier than standard treatment with prednisone and needs

further evaluation in larger studies[219]. Alternatively oral cholecystographic agents (such as sodium ipodate or sodium iopanoate [neither of which is available in the USA at present]) may be used safely and effectively for the management of the thyrotoxicosis in these patients even when they have relapsed after corticosteroid therapy[220]. The recurrence rate of subacute thyroiditis after cessation of prednisolone therapy is about 20% but no difference has been found in routine laboratory data between recurrent and non-recurrent groups of patients[221]. Levothyroxine administration has been touted as useful in situations where the patient is not already hyperthyroid due to the release of thyroidal contents into the circulation[116]. The effectiveness of this strategy on shortening the clinical course or reducing the frequency of recurrence is not clear. It is also of course necessary to administer thyroid hormones, at least transiently, if the patient enters a phase of symptomatic hypothyroidism subsequent to the acute inflammation. Levothyroxine should only be administered for up to a year, otherwise, the return of thyroid function to normal, which presumably is facilitated by TSH, may be prevented or delayed. During the recovery process, there may be a marked but transient increase in the 24 hour radioactive iodine uptake which can reach levels typical of Graves' disease but thyrotoxicosis is not simultaneously present. This elevation of iodine uptake occurs prior to re-establishment of normal thyroid function and should not be confused (taken out of context) with hyperthyroidism due to Graves' Disease. Surgical intervention is not the primary treatment for subacute thyroiditis. Experience from the Mayo clinic[222] has shown however that if surgery is performed for a clinically indeterminate thyroid nodule, resection is safe and with low morbidity. Because of the possibility of associated papillary cancer further cytological examination should be performed in patients presenting with a persistent hypoechoic area larger than 1 cm by ultrasonography[203].

Prognosis

In 90% or more of patients, there is a complete and spontaneous recovery and a return to normal thyroid function. However, the thyroid glands of patients with subacute thyroiditis may exhibit irregular scarring between islands of residual functioning parenchyma, although the patient has no symptoms. SAT may recur in upto 2.8 to 4 % of population with subacute thyroiditis[166, 223]. Up to 10% of the patients may become hypothyroid and require permanent replacement with levothyroxine. In a retrospective study of 252 patients with SAT permanent hypothyroidism occurred in 5.9% and all these had bilateral hypoechoic areas on thyroid ultrasound at initial presentation suggesting that this may be a useful prognostic marker for the potential development of thyroid dysfunction after SAT[224]. However, permanent hypothyroidism is significantly less common in SAT compared to the outcome noted in amiodarone induced thyrotoxicosis type 2 (destructive thyroiditis)[225]. It is of interest that elevated levels of serum thyroglobulin may persist well over a year after the initial diagnosis, indicating that disordered follicular architecture and/or low grade inflammation can persist for a relatively long period[226].

A minority (< 1%) of those presenting with clinical SAT in Japan have been reported to return (n= 7) a mean 4.7 months later with findings consistent with Graves' disease (GD)[209]. Review of the other 26 cases summarized in the report of Nakano et al. indicates a similar interval

between the diagnosis of SAT and subsequent GD presentation, a clearly elevated RAIU in the GD phase of all the reports where an uptake is reported (14/26 [54%]) and a change in thyroid antibody positivity in 50% of those evaluated in both (6/26 [23%]) the SAT and GD presentation[209]. Combining Nakano's cases with their review of the literature, fully 21/31 [68%] of cases labeled as SAT were diagnosed clinically without a radioactive iodine uptake assessment and a further 4/12 [33%] of those diagnosed as SAT with a RAIU available, had uptakes greater than 10% at the time of the SAT diagnosis[209]. This brings into question the true incidence of this reported transition from presumably non-autoimmune SAT to clearly immune mediated GD.

RIEDEL'S THYROIDITIS

Initially described by Semple in 1864 and Bolby in 1888[227], the condition then again reported in 1896 by Riedel as an "eisenharte" (iron hard) fixed and usually painless enlargement of the thyroid [228-230] is a chronic sclerosing thyroiditis, occurring especially in women, that tends to progress inexorably to complete destruction of the thyroid gland and frequently causes pressure symptoms in the neck [228, 231, 232]. It is exceedingly rare with estimated incidence of 1.06 cases per 100,000 population and 37/57,000 (0.06%) surgical outcomes over a 64 year period[233]. In the Mayo Clinic series [233] it occurred approximately one-fiftieth as frequently as Hashimoto's thyroiditis. It is more frequent in women (F:M 3.1:1)[48, 133, 228, 234] who were recently reported to represent 81% of those with confirmed Riedel's in a Mayo clinic series[235]. Riedel's thyroiditis is principally reported to occur in the 30- to 50 year age group[48, 234, 235].

Pathology

The thyroid gland is normal in size or enlarged, focally or symmetrically involved, and extremely (woody) hard. The gland is replaced by the inflammatory process which may extend into adjacent structures including parathyroid, skeletal muscle, nerves, blood vessels as well as the trachea[236]. Gross observation of the mass reveals a pale gray appearance similar to a malignant lesion[237]. There are no tissue planes visible and the cut surface of the mass is stark white due to the hypovascularity of the tissue[238]. Histologically normal tissue is replaced by inflammatory cells, predominantly lymphocytes, plasma cells, eosinophils[234, 239], and small amounts of colloid[240-242] in a dense matrix of hyalinized connective tissue. Characteristically, an inflammatory reaction of the venous vascular structures has been described[237]. An oft stated criterion useful in assuring the pathologic diagnosis is to note the absence of granulomatous tissue and malignancy[234, 237, 238]. A potentially difficult differential diagnostic decision may be encountered with rare sarcomas of the thyroid region[243] or with the pauci-cellular variant of anaplastic thyroid cancer which although similar in gross appearance will have distinctive histopathologic immunohistochemical findings[244].

Etiology

Although the etiology is unclear, Riedel's has been characterized in various ways including as the cervical manifestation of a systemic fibrosing disorder with identical histopathological appearance[245]. Further Riedel's has been called a variant of Hashimoto's, a primary infiltrative disease of the thyroid and even a manifestation of end stage deQuervain's thyroiditis[231, 240, 246, 247]. Riedel's has been reported following subacute thyroiditis [247] and a case of concurrent Riedel's, Hashimoto's and acute thyroiditis has also been reported [248]. The report of a case of Graves' disease following Riedel's thyroiditis [249] and the observation that the B cell proliferation observed in the course of these diseases has been shown to be polyclonal [250] supports the notion of autoimmune mechanisms in the etiology of the Riedel's condition. The occurrence of marked tissue eosinophilia and the extracellular deposition of eosinophil granule major basic protein suggests a role for eosinophils and their products in the development of fibrosis in Riedel's thyroiditis [239]. Fibrosis may also be related to the action of TGF beta 1, as seen in murine thyroiditis [251]. Most recently links between Hashimoto's, IgG4-related systemic disease (IgG4-RSD) and Riedel's have been reported [252-254]. Supporting evidence showing the presence of IgG4-bearing plasma cells in thyroidectomy specimens and other affected organs [254, 255]. A recent comprehensive review of potential etiology has been published[236].

IgG4-related disease (IgG4-RD) was first described in 1961 as a distinctive presentation of pancreatitis which was observed to be associated with hypergammaglobulinemia[256]. A specific association with IgG4 was published in 2001[257] and eventually an international consensus was established to define the criteria for recognizing IgG4-RD[258, 259]. Through this understanding of pathophysiology the term IgG4-RD has been adopted to describe a common underlying pathology found in a variety of fibrosing disorders which over the years have been designated in various ways primarily based on the organ of involvement and the initial authors of reports describing their occurrence. Under the umbrella of IgG4-RD, newer nomenclature captures entities such as Mikulicz syndrome as IgG4 related dacryoadentis and sialadenitis and Riedel's thyroiditis as IgG4 related thyroid disease[260]. One or several organs may be involved at the time of diagnosis or subsequent to the identification of IgG4-RD in a particular organ. The most frequently involved organs include the pancreas, bile ducts, salivary glands, lachrymal glands and kidneys[260]. The majority of cases are identified by the presence of characteristic fibrosing pathology and it is expected that serum IgG4 levels are elevated in most cases. The diagnosis of IgG4-RD is based on the identification of a (1) mass in one or more organs associated with an (2) elevated serum IgG4 level (greater than 1.35 g/L) and (3) histopathology demonstrating marked lymphocytic and plasma cell infiltration, more than 10 IgG4 positive plasma cells per high powered field (greater than a 40% IgG4/IgG ratio) and storiform fibrosis[258, 261]. Definitive diagnosis is assured when all 3 criteria are present, probable diagnosis when the first and 3rd criteria are met and possible when only the 1st and second criteria are present[260].

Based on these criteria therefore, the position of Riedel's thyroiditis among the IgG4-RDs would be considered probable as the vast majority of cases reported thus far are not associated with elevated serum IgG4 levels although the typical histopathologic criteria are met when applied. A recent review of 10 cases studied in Japan confirm the IgG4-RD connection in histopathological data but note a paucity of serum IgG4 levels in their summary of the published literature[262].

Most recent cases noting this association and including the association with IgG4-RD in their titles document the first and third diagnostic criteria[254, 262-264] while only a few have documented and elevated serum IgG4 level[265, 266].

Clinical Features

Riedel's thyroiditis usually presents as a hard thyroid mass, frequently associated with compressive symptoms[48, 228, 231, 233-235, 267] and historically has been diagnosed by a surgeon faced with an inflammatory mass of fibrosclerosing tissue[268, 269] when expecting a thyroid tumor[241]. Intraoperative diagnostic confusion with anaplastic thyroid cancer[244], sarcoma of the thyroid[243], thyroid lymphoma[270] or fibrosing Hashimoto's thyroiditis[271] have been reported. A case of asymptomatic Riedel's associated with a benign follicular adenoma has been recently reported[272]. Riedel's may occur in a multinodular goiter or as a rapidly growing hard neck mass in a previously normal gland mimicking thyroid cancer[269, 273, 274]. As the extent of the fibrosis increases or concomitant Hashimoto's is present, involvement of a critical mass of the thyroid tissue results in primary hypothyroidism in 25-80% of cases[231, 235, 241, 242, 275]. Antithyroid antibodies are present in 67-90% of reported cases[232, 235]. Extension of the inflammatory process into underlying parathyroid glands may result in non-surgical hypoparathyroidism[275-280] in up to 14% cases encountered[235]. The fibrosis may remain relatively stable or progress resulting in local complications by compressing the trachea or esophagus and resulting in symptoms of local pressure, dyspnea, dysphagia as well as stridor out of proportion of the size of the mass[281, 282], with subsequent hoarseness, and aphonia, with involvement of the recurrent laryngeal nerves[271, 278]. Further extension of the inflammatory process involving neck structure can result in Tolosa-Hunt syndrome[283], Horner's syndrome[278], occlusive phlebitis of cervical vessels[284-286]. The occurrence of cerebral sinus thrombosis suggests that Riedel's thyroiditis may cause venous stasis, vascular damage, and possibly hypercoagulability [287]. Estimates as high as 38% associate Riedel's thyroiditis with similar fibro-sclerotic processes in other areas[235]. Subcutaneous fibrosclerosis has also been noted but it is very rare[288]. The lesions appear in the lacrimal glands, orbits[289], parotid glands[290], mediastinum[233, 235, 237, 241], coronary arteries[235], retroperitoneal tissues[231, 233, 275, 291, 292], bile ducts[234, 293] and pancreas[293] in varying combinations in the syndrome of multifocal fibro-sclerositis [294, 295].

Clinical Evaluation

Initially the patient with a thyroid mass will need an assessment of thyroid function, and may benefit from screening thyroid antibodies[296]. A complete blood count reveals normal to elevated white blood cell counts. The erythrocyte sedimentation rate is usually moderately elevated[240, 241]. Due to the potential of hypoparathyroidism an assessment of calcium status is prudent[236]. Ultrasonography of the thyroid typically reveals a diffuse, hypoechoic, hypovascular appearance due to the extensive fibrosing process[249, 269, 275, 297, 298]. Unique to the findings in Riedel's thyroiditis is an encasement of the carotid arteries, not typically seen in other forms of multinodular or Hashimoto's goiter[235, 299]. Sonographic elastography demonstrates significant stiffness of the tissue compared to normal thyroid[299].

At this point in the evaluation a fine needle aspiration (FNA) of the thyroid mass is usually obtained. FNA results are typically non-diagnostic due the lack of thyroid follicular cells[48, 234, 235, 238] but may contain evidence of the inflammatory process[235], fibrous tissue and myofibroblasts[300], or even cytopathology findings consistent with follicular neoplasm[277]. A novel case illustrates a potential use of FNA to obtain protein used in proteomic analysis which was successful in differentiating the tissue of a patient with Riedel's thyroiditis from the tissue profile of anaplastic thyroid cancer[301].

In patients with significant obstructive symptomatology a neck computed tomography (CT) study may be ordered to assess tracheal integrity. CT images characteristically demonstrate hypodense tissue which does not enhance with iodinated contrast in the affected area[297]. CT images readily reveal extrathyroidal extension of the inflammatory process[297, 302], and have been reported to document arterial encasement in about half of subjects and jugular involvement in about one third of cases[235]. Magnetic resonance imaging (MRI) can be expected to show hypointense images on both T1 and T2 weighted images[297] and variable enhancement patterns after gadolinium enhancement[297, 298, 302-304]. Unlike the hypointense images produced by CT and MRI, Fluorine-18 fluorodeoxyglucose [FDG] positron emission tomographic (PET) images have shown metabolic activity not only in extrathyroidal masses associated with the systemic inflammatory process but also increased glucose metabolism in the Riedel's thyroid, likely as a result of active inflammation involving lymphocytes, plasma cells and fibroblast proliferation [299, 305, 306]. FDG metabolic activity can also be used to assess a patient's response to therapy [305, 306] but not all reports of this phenomenon had documented this effect[299].

Although not typically indicated in the evaluation of a eu- or hypothyroid individual with a thyroid mass, ^{99m}Tc -pertechnetate or $^{123}/^{131}\text{I}$ scanning in Riedel's is typically compromised due to low uptake and patchy images typical of other forms of chronic thyroiditis[234, 240, 241]. An exception to the utility of radio nuclide scanning is found in exactly the circumstance where a nuclear medicine scan is indicated that being in the thyrotoxic patient presenting with the thyroid mass. In those with Graves' disease or a toxic thyroid nodule, the hyperfunctioning portion of the thyroid is indeed well visualized while the portion involved with Riedel's typically demonstrates no uptake[249]. Finally, it has recently been reported that gallium scanning may. As expected, also demonstrate significant uptake in the Riedel's lesion[101].

Establishing the diagnosis of Riedel's requires histopathologic confirmation at the present time. Biopsy material may be obtained by Tru-cut needle biopsy[307], open biopsy[48] or at the time of decompressive thyroidectomy. Histopathologic findings required to establish this diagnosis include: 1) The presence of an inflammatory process in the thyroid with extension into surrounding tissue. 2) The inflammatory infiltrate should contain no giant cells, lymphoid follicles, oncocytes or granulomas. 3) There should be evidence of occlusive phlebitis. 4) There should be no evidence of thyroid malignancy[308]. In light of the recent work defining Riedel's as a potential manifestation of the IgG4-related systemic sclerosing disease, the potential role of incorporating the presence of immunohistochemical assessment of tissue lymphocytes and the measurement of IgG4 levels into working diagnostic criteria remains to be defined.

Management of Riedel's Thyroiditis

Although there is no specific therapy for Riedel's thyroiditis, several management strategies are available dependent on the clinical features of the disease in the individual patient. Patients commonly undergo surgery for relief of obstructive symptoms. Histopathology allows for the definitive establishment of the diagnosis. Most are then treated medically for associated hormone deficiencies with levothyroxine and /or calcium along with calcitriol, but with exception of one case where reduction of the size of the inflammatory mass was observed[274], this supplementation is not thought to influence the course of the disease. Finally, anti-inflammatory treatment aimed at diminishing the inflammatory mass is applied and may result in resolution of limited biochemical findings such as primary hypoparathyroidism[280].

Surgical therapy for debulking and symptoms relief should usually be limited to isthmusectomy [48, 234, 267, 277] when total thyroidectomy is not possible. Due to the obliteration of tissue planes associated with the advancing inflammatory process there is an enhanced danger of hypoparathyroidism and recurrent laryngeal nerve injury even when limited surgery is performed by experienced surgical specialists as documented in a recent series from the Mayo clinic where 39% of Riedel's patients suffered surgical complications[235]. Previous and contemporary experience therefore recommends that extensive surgical procedures be considered inappropriate [48, 235, 238, 277].

Medical therapy to arrest progression of symptomatic disease should be pursued after establishment of a firm diagnosis. Corticosteroid therapy has been found to be effective in some cases [232, 276, 280, 287, 294, 303, 307, 309-314], probably those with active inflammation[254, 313]. Initial doses of up to 100mg per day of prednisone have been used[234] but sustained improvement has been reported with lower doses of 15-60 mg per day [270, 278, 294, 309, 312, 314]. There are no controlled trials of steroid therapy in Riedel's and although some patients obtain long term benefit after steroid withdrawal [245, 294, 313] others may relapse usually leading to the reintroduction of glucocorticoids or the addition of alternative anti-inflammatory therapy[278, 315, 316]. The reasons for this variation are unclear but inflammatory activity and duration of disease may be relevant factors. Most recently, the observation that smoking history may play a role in the responsiveness of Riedel's pathology to glucocorticoid therapy has been published[235].

In those who fail to respond to steroid therapy or relapse after withdrawal, tamoxifen therapy should be tried. Several reports have described an encouraging response with this agent, admittedly in only a small number of patients [278, 280, 315, 317-322]. It is possible that tamoxifen acts in Riedel's by inhibition of fibroblast proliferation through the stimulation of TGF beta [323-325]. Tamoxifen in combination with prednisone or tamoxifen as monotherapy have both been reported to be effective [278, 315, 320, 322]. There appears to be a persistent benefit to tamoxifen therapy during continued application in most but not all cases [235, 316]. Recent data on effective therapy with other immunosuppressive agents indicates that a combination of mycophenolate mofetil and prednisone has been observed to have successfully treated an

individual who failed a prednisone and tamoxifen combination [316] and Rituximab has also been reported to be useful[264]. The potential usefulness of this intervention awaits confirmation.

Summary of Riedel's Thyroiditis

Riedel's thyroiditis should be suspected in patients with a thyroid mass and unique clinical features. Findings increasing the likelihood of Riedel's include local restrictive or infiltrative symptoms out of proportion to the size or extent of the mass or simultaneous hypocalcemia. Surgical intervention should be limited to rule out the presence of malignancy and obtain the histopathologic confirmation. Once Riedel's thyroiditis is established, a search for related fibrotic conditions and medical treatment should be pursued. Replacement of thyroxine and when appropriate, calcium and vitamin D therapy should be begun along with anti-inflammatory medications.

RARE INFLAMMATORY OR INFILTRATIVE DISEASES

In addition to the varieties of thyroiditis already mentioned, which are diseases specifically of the thyroid gland, generalized or systemic diseases may also involve the thyroid gland [48]. The lesions of sarcoid may appear in the thyroid gland of 1-4% of patients with systemic sarcoidosis[326]. Thyroid dysfunction has been reported very infrequently (1-3%)[327] in systemic sarcoidosis but a recent series of patients with cutaneous sarcoidosis noted abnormal TSH values in 26% compared to the US population expectation of about 10%[327]. Most thyroid dysfunction was mild, a male to female ratio of abnormal thyroid function of 1:1 was noted, Caucasians were more frequently affected than African Americans and 20% of those with abnormal TSH were classified as hypothyroid[327]. Infiltration of the thyroid with sarcoidosis is reported to occur in about 5% of patients with sarcoidosis[328]. Multinodular goiter has recently been described as an initial presenting manifestation in a woman eventually diagnosed with systemic sarcoidosis[326]. This case illustrates the difficulty in diagnosing the cause of supine dyspnea in patients with sarcoidosis, illustrating the potential of a thyroid contribution to the overall clinical picture[326].

Deposits of amyloid are quite common in systemic amyloidosis[329] and rarely causes goiter with more than 200 cases in the world's literature[329-332]. Although senile transthyretin amyloidosis is primarily associated with amyloid deposits in the heart, familial forms of amyloidosis due to transthyretin gene mutations are associated with deposits of amyloid in multiple tissues[333]. Amyloid goiter with transthyretin activity in a patient with chronic renal failure has been reported [333]. Clinically, an amyloid goiter may be progressive, diffuse and rapidly lead to compressive symptoms[329, 330]. Thyroid function in association with an amyloid goiter is normal in 2/3 of cases, 1/7 present with hypothyroidism and fewer demonstrate other abnormalities of thyroid function[329]. In addition to the focal deposition of amyloid in thyroid tissues associated with most cases of medullary thyroid cancer[334], several cases of papillary thyroid cancer have been reported in association of amyloid goiter[329, 335-337]. Amyloid goiter may be readily diagnosed by fine needle aspiration biopsy[338] and has been

reported in conjunction with infiltration of other endocrine organs such as the pituitary[331]. It has been suggested that the thyroid FNA is both an accurate and relatively safe site of biopsy to confirm the presence of systemic amyloidosis[329].

Painless thyroiditis has been noted in a woman with rheumatoid arthritis and secondary amyloidosis infiltrating the thyroid gland [339]. Radiotherapy for tonsillar carcinoma has been reported to result in thyroiditis [340]. Irradiation to the thyroid during therapy for breast cancer or lymphoma can also induce hypothyroidism. Following ¹³¹I therapy for Graves' disease or toxic multinodular goiter, thyroiditis which is occasionally symptomatic, may develop. This situation is discussed in Chapters 11 and 18. Therapy should be directed toward the primary disease rather than the thyroid, but administration of thyroid hormone may be necessary if destruction of thyroid tissue is sufficient to produce hypothyroidism. Finally, surgery to the neck, associated with mechanical manipulation of the thyroid during laryngectomy or parathyroid surgery can result in a painless subacute thyroiditis like picture [341-343].

Acknowledgement: The authors are grateful to the extensive groundwork performed by Dr. John Lazarus, the founding author of this chapter. Additionally, we are privileged to update this summary with the most recent developments in the field while maintaining the historical perspective of those who have preceded us.

1. Chi, H., et al., *Acute suppurative thyroiditis in children*. *Pediatr Infect Dis J*, 2002. **21**(5): p. 384-7.
2. Chang, P., et al., *Clinical characteristics and management of acute suppurative thyroiditis in children*. *J Formos Med Assoc*, 2002. **101**(7): p. 468-71.
3. Brook, I., *Microbiology and management of acute suppurative thyroiditis in children*. *Int J Pediatr Otorhinolaryngol*, 2003. **67**(5): p. 447-51.
4. Hatabu, H., et al., *Acute suppurative thyroiditis associated with piriform sinus fistula: sonographic findings*. *AJR Am J Roentgenol*, 1990. **155**(4): p. 845-7.
5. Parida, P.K., S. Gopalakrishnan, and S.K. Saxena, *Pediatric recurrent acute suppurative thyroiditis of third branchial arch origin--our experience in 17 cases*. *Int J Pediatr Otorhinolaryngol*, 2014. **78**(11): p. 1953-7.
6. Lucaya, J., et al., *Congenital pyriform sinus fistula: a cause of acute left-sided suppurative thyroiditis and neck abscess in children*. *Pediatr Radiol*, 1990. **21**(1): p. 27-9.
7. Miyauchi, A., et al., *Acute suppurative thyroiditis; infection in thyroid nodules or infection through a piriform sinus fistula*. *Thyroidol. Clin Exp* 1998. **10**: p. 75-79.
8. Miyauchi, A., et al., *Piriform sinus fistula and the ultimobranchial body*. *Histopathology*, 1992. **20**(3): p. 221-7.
9. Shah, S.S. and S.G. Baum, *Diagnosis and Management of Infectious Thyroiditis*. *Curr Infect Dis Rep*, 2000. **2**(2): p. 147-153.
10. Fukata, S., et al., *Acute suppurative thyroiditis caused by an infected piriform sinus fistula with thyrotoxicosis*. *Thyroid*, 2002. **12**(2): p. 175-8.
11. Gan, Y.U. and S.L. Lam, *Imaging findings in acute neck infection due to pyriform sinus fistula*. *Ann Acad Med Singapore*, 2004. **33**(5): p. 636-40.

12. Paes, J.E., et al., *Acute bacterial suppurative thyroiditis: a clinical review and expert opinion*. *Thyroid*, 2010. **20**(3): p. 247-55.
13. Hendrick, J.W., *Diagnosis and management of thyroiditis*. *J Am Med Assoc*, 1957. **164**(2): p. 127-33.
14. Yu, E.H., et al., *Suppurative Acinetobacter baumannii thyroiditis with bacteremic pneumonia: case report and review*. *Clin Infect Dis*, 1998. **27**(5): p. 1286-90.
15. Minhas, S.S., J.C. Watkinson, and J. Franklyn, *Fourth branchial arch fistula and suppurative thyroiditis: a life-threatening infection*. *J Laryngol Otol*, 2001. **115**(12): p. 1029-31.
16. Nicoucar, K., et al., *Management of congenital fourth branchial arch anomalies: a review and analysis of published cases*. *J Pediatr Surg*, 2009. **44**(7): p. 1432-9.
17. Sheng, Q., et al., *Diagnosis and management of pyriform sinus fistula: experience in 48 cases*. *J Pediatr Surg*, 2014. **49**(3): p. 455-9.
18. Acocelia, A., et al., *Acute thyroiditis of odontogenic origin*. *Minerva Stomatol.*, 2007. **56**: p. 461-467.
19. Vandjme, A., et al., *Nocardiosis revealed by thyroid abscess in a liver--kidney transplant recipient*. *Transpl Int*, 2001. **14**(3): p. 202-4.
20. Teckie, G., et al., *Thyrotoxicosis followed by Hypothyroidism due to Suppurative Thyroiditis Caused by in a Patient with Advanced Acquired Immunodeficiency Syndrome*. *Eur Thyroid J*, 2014. **3**(1): p. 65-68.
21. Kazi, S., et al., *Salmonella thyroid abscess in human immunodeficiency virus-positive man: a diagnostic pitfall in fine-needle aspiration biopsy of thyroid lesions*. *Diagn Cytopathol*, 2015. **43**(1): p. 36-9.
22. Massolt, E.T., et al., *Acute Candida thyroiditis complicated by abscess formation in a severely immunocompromised patient*. *J Clin Endocrinol Metab*, 2014. **99**(11): p. 3952-3.
23. Berger, S.A., et al., *Infectious diseases of the thyroid gland*. *Rev Infect Dis*, 1983. **5**(1): p. 108-22.
24. Fernandez, J.F., et al., *Acute fungal thyroiditis in a patient with acute myelogenous leukaemia*. *J Intern Med*, 1991. **230**(6): p. 539-41.
25. Gandhi, R.T., S.R. Tollin, and E.W. Seely, *Diagnosis of Candida thyroiditis by fine needle aspiration*. *J Infect*, 1994. **28**(1): p. 77-81.
26. McAninch, E.A., et al., *Coccidiomycosis thyroiditis in an immunocompromised host post-transplant: case report and literature review*. *J Clin Endocrinol Metab*, 2014. **99**(5): p. 1537-42.
27. Alvi, M.M., et al., *Aspergillus thyroiditis: a complication of respiratory tract infection in an immunocompromised patient*. *Case Rep Endocrinol*, 2013. **2013**: p. 741041.
28. Imai, C., et al., *Acute suppurative thyroiditis as a rare complication of aggressive chemotherapy in children with acute myelogeneous leukemia*. *Pediatr Hematol Oncol*, 2002. **19**(4): p. 247-53.
29. Yildar, M., G. Demirpolat, and M. Aydin, *Acute suppurative thyroiditis accompanied by thyrotoxicosis after fine-needle aspiration: treatment with catheter drainage*. *J Clin Diagn Res*, 2014. **8**(11): p. ND12-4.

30. Unluturk, U., K. Ceyhan, and D. Corapcioglu, *Acute suppurative thyroiditis following fine-needle aspiration biopsy in an immunocompetent patient*. J Clin Ultrasound, 2014. **42**(4): p. 215-8.
31. Inoue, K., et al., *Right-sided acute suppurative thyroiditis caused by infectious endocarditis*. Intern Med, 2011. **50**(23): p. 2893-7.
32. Chiovato, L., et al., *Salmonella brandenburg: a novel cause of acute suppurative thyroiditis*. Acta Endocrinol (Copenh), 1993. **128**(5): p. 439-42.
33. Dai, M.S., et al., *Suppurative salmonella thyroiditis in a patient with chronic lymphocytic leukemia*. Ann Hematol, 2003. **82**(10): p. 646-8.
34. Su, D.H. and T.S. Huang, *Acute suppurative thyroiditis caused by Salmonella typhimurium: a case report and review of the literature*. Thyroid, 2002. **12**(11): p. 1023-7.
35. Bukvic, B., A. Diklic, and V. Zivaljevic, *Acute suppurative klebsiella thyroiditis: a case report*. Acta Chir Belg, 2009. **109**(2): p. 253-5.
36. Wu, S.W., et al., *A Salmonella infection complicated with suppurative thyroiditis and ruptured aortic mycotic aneurysm in a renal transplant recipient*. Transplant Proc, 2008. **40**(10): p. 3759-63.
37. Fernandez Pena, C., et al., *Pasteurella spp: a new microorganism to the cause of acute suppurative thyroiditis*. An Med Interna, 1999. **16**: p. 637-638.
38. McLaughlin, S.A., S.L. Smith, and S.E. Meek, *Acute suppurative thyroiditis caused by Pasteurella multocida and associated with thyrotoxicosis*. Thyroid, 2006. **16**(3): p. 307-10.
39. Spitzer, M., S. Alexanian, and A.P. Farwell, *Thyrotoxicosis with Post-Treatment Hypothyroidism in a Patient with Acute Suppurative Thyroiditis Due to Porphyromonas*. Thyroid, 2011.
40. Iniguez, J.L., V. Duyckaerts, and J. Badoual, *[Acute thyroiditis caused by Eikenella corrodens and abnormality of the left pyriform sinus]*. Arch Fr Pediatr, 1989. **46**(10): p. 745-7.
41. Queen, J.S., et al., *Acute suppurative thyroiditis caused by Eikenella corrodens*. J Pediatr Surg, 1988. **23**(4): p. 359-61.
42. Yoshino, Y., et al., *A pediatric patient with acute suppurative thyroiditis caused by Eikenella corrodens*. J Infect Chemother, 2010. **16**(5): p. 353-5.
43. Nieuwland, Y., K.Y. Tan, and J.W. Elte, *Miliary tuberculosis presenting with thyrotoxicosis*. Postgrad Med J, 1992. **68**(802): p. 677-9.
44. Das, D.K., et al., *Fine needle aspiration cytology diagnosis of tuberculous thyroiditis. A report of eight cases*. Acta Cytol, 1992. **36**(4): p. 517-22.
45. Orlandi, F., et al., *Tubercular involvement of the thyroid gland: a report of two cases*. Horm Res, 1999. **52**(6): p. 291-4.
46. Terzidis, K., et al., *Thyroid tuberculosis*. Hormones (Athens), 2007. **6**(1): p. 75-9.
47. Kataria, S.P., et al., *Primary tuberculosis of the thyroid gland: a case report*. Asian Pac J Trop Biomed, 2012. **2**(10): p. 839-40.
48. Singer, P.A., *Thyroiditis. Acute, subacute, and chronic*. Med Clin North Am, 1991. **75**(1): p. 61-77.

49. Szabo, S.M. and D.B. Allen, *Thyroiditis. Differentiation of acute suppurative and subacute. Case report and review of the literature*. Clin Pediatr (Phila), 1989. **28**(4): p. 171-4.
50. Karatoprak, N., et al., *Actinomycotic suppurative thyroiditis in a child*. J Trop Pediatr, 2005. **51**(6): p. 383-5.
51. Park, Y.H., J.H. Baik, and J. Yoo, *Acute thyroiditis of actinomycosis*. Thyroid, 2005. **15**(12): p. 1395-6.
52. Trites, J. and M. Evans, *Actinomycotic thyroiditis in a child*. J Pediatr Surg, 1998. **33**(5): p. 781-2.
53. Moinuddin, S., H. Barazi, and M. Moinuddin, *Acute blastomycosis thyroiditis*. Thyroid, 2008. **18**(6): p. 659-61.
54. Karabinis, A., et al., [*Acute necrotic thyroiditis caused by Candida albicans immediately after acute hemorrhagic rectocolitis*]. Presse Med, 1993. **22**(1): p. 34.
55. Carriere, C., et al., *Nocardia thyroiditis: unusual location of infection*. J Clin Microbiol, 1999. **37**(7): p. 2323-5.
56. Lewin, S.R., A.C. Street, and J. Snider, *Suppurative thyroiditis due to Nocardia asteroides*. J Infect, 1993. **26**(3): p. 339-40.
57. Avram, A.M., et al., *Cryptococcal thyroiditis and hyperthyroidism*. Thyroid, 2004. **14**(6): p. 471-4.
58. Zavascki, A.P., A.L. Maia, and L.Z. Goldani, *Pneumocystis jiroveci thyroiditis: report of 15 cases in the literature*. Mycoses, 2007. **50**(6): p. 443-6.
59. Orkar, K.S., et al., *Pyogenic thyroiditis and HIV infection*. West Afr J Med, 2001. **20**(2): p. 173-5.
60. Tien, K.J., et al., *Acute suppurative thyroiditis with deep neck infection: a case report*. Thyroid, 2007. **17**(5): p. 467-9.
61. Iwama, S., Y. Kato, and S. Nakayama, *Acute suppurative thyroiditis extending to descending necrotizing mediastinitis and pericarditis*. Thyroid, 2007. **17**(3): p. 281-2.
62. Premawardhana, L.D., J.P. Vora, and M.F. Scanlon, *Suppurative thyroiditis with oesophageal carcinoma*. Postgrad Med J, 1992. **68**(801): p. 592-3.
63. Valina, S., et al., [*Abscess Formation after Puncture of a Thyroid Cyst - A Case Report.*] Zentralbl Chir, 2011.
64. Kale, S.U., A. Kumar, and V.C. David, *Thyroid abscess--an acute emergency*. Eur Arch Otorhinolaryngol, 2004. **261**(8): p. 456-8.
65. Jimenez-Heffernan, J.A., et al., *Massive thyroid tumoral embolism from a breast carcinoma presenting as acute thyroiditis*. Arch Pathol Lab Med, 2004. **128**(7): p. 804-6.
66. Nishihara, E., et al., *Acute suppurative thyroiditis after fine-needle aspiration causing thyrotoxicosis*. Thyroid, 2005. **15**(10): p. 1183-7.
67. Chen, H.W., et al., *Secondary infection and ischemic necrosis after fine needle aspiration for a painful papillary thyroid carcinoma: a case report*. Acta Cytol, 2006. **50**(2): p. 217-20.
68. Sicilia, V. and S. Mezitis, *A case of acute suppurative thyroiditis complicated by thyrotoxicosis*. J Endocrinol Invest, 2006. **29**(11): p. 997-1000.
69. Hopwood, N.J. and R.P. Kelch, *Thyroid masses: approach to diagnosis and management in childhood and adolescence*. Pediatr Rev, 1993. **14**(12): p. 481-7.

70. Sai Prasad, T.R., et al., *Acute suppurative thyroiditis in children secondary to pyriform sinus fistula*. *Pediatr Surg Int*, 2007. **23**(8): p. 779-83.
71. Wasniewska, M., et al., *Acute suppurative thyroiditis in childhood: spontaneous closure of sinus pyriform fistula may occur even very early*. *J Pediatr Endocrinol Metab*, 2007. **20**(1): p. 75-7.
72. Dugar, M., et al., *Unilateral hypopharyngitis, cellulitis, and a multinodular goiter: a triad of findings suggestive of acute suppurative thyroiditis*. *AJNR Am J Neuroradiol*, 2009. **30**(10): p. 1944-6.
73. Mohan, P.S., et al., *Thyroglossal duct cysts: a consideration in adults*. *Am Surg*, 2005. **71**(6): p. 508-11.
74. Robazzi, T.C., C. Alves, and M. Mendonca, *Acute suppurative thyroiditis as the initial presentation of juvenile systemic lupus erythematosus*. *J Pediatr Endocrinol Metab*, 2009. **22**(4): p. 379-83.
75. Cabizuca, C.A., et al., *Acute thyroiditis due to septic emboli derived from infective endocarditis*. *Postgrad Med J*, 2008. **84**(994): p. 445-6.
76. Cases, J.A., et al., *Recurrent acute suppurative thyroiditis in an adult due to a fourth branchial pouch fistula*. *J Clin Endocrinol Metab*, 2000. **85**(3): p. 953-6.
77. Takai, S.I., et al., *Internal fistula as a route of infection in acute suppurative thyroiditis*. *Lancet*, 1979. **1**(8119): p. 751-2.
78. Yamashita, J., et al., *Acute suppurative thyroiditis in an asymptomatic woman: an atypical presentation simulating thyroid carcinoma*. *Clin Endocrinol (Oxf)*, 1994. **40**(1): p. 145-9; discussion 149-50.
79. Miyauchi, A., et al., *Piriform sinus fistula. A route of infection in acute suppurative thyroiditis*. *Arch Surg*, 1981. **116**(1): p. 66-9.
80. Nonomura, N., et al., *Surgical approach to pyriform sinus fistula*. *Am J Otolaryngol*, 1993. **14**(2): p. 111-5.
81. Himi, T. and A. Kataura, *Distribution of C cells in the thyroid gland with pyriform sinus fistula*. *Otolaryngol Head Neck Surg*, 1995. **112**(2): p. 268-73.
82. Bar-Ziv, J., et al., *Branchial pouch sinus tract from the piriform fossa causing acute suppurative thyroiditis, neck abscess, or both: CT appearance and the use of air as a contrast agent*. *AJR Am J Roentgenol*, 1996. **167**(6): p. 1569-72.
83. Gaafar, H. and F. El-Garem, *Acute thyroiditis with gas formation*. *J Laryngol Otol*, 1975. **89**(3): p. 323-7.
84. Bussman, Y.C., et al., *Suppurative thyroiditis with gas formation due to mixed anaerobic infection*. *J Pediatr*, 1977. **90**(2): p. 321-2.
85. Reksoprawiro, S., *Suppurative thyroiditis with gas formation*. *Asian J Surg*, 2003. **26**(3): p. 180-2.
86. Al-Kordi, R.S., E. Alenizi, and A.H. Elgazzar, *Acute suppurative thyroiditis with abscess, gas formation, and thyrotoxic crisis*. *Nuklearmedizin*, 2008. **47**(4): p. N44-6.
87. Lemariey, Hamelin, and Muler, *[Acute thyroiditis complicating mediastinitis]*. *Ann Otolaryngol*, 1955. **72**(7): p. 571-3.
88. Dordain, M.L., et al., *[Suppurative mediastinitis secondary to acute thyroiditis in a patient under corticotherapy]*. *Presse Med*, 1997. **26**(7): p. 319-20.

89. Pereira, O., et al., *Fatal descending necrotizing mediastinitis secondary to acute suppurative thyroiditis developing in an apparently healthy woman*. *Thyroid*, 2010. **20**(5): p. 571-2.
90. Larsen, P.R., *Thyroidal triiodothyronine and thyroxine in Graves' disease: correlation with presurgical treatment, thyroid status, and iodine content*. *J Clin Endocrinol Metab*, 1975. **41**(06): p. 1098-104.
91. Yung, B.C., et al., *Acute suppurative thyroiditis due to foreign body-induced retropharyngeal abscess presented as thyrotoxicosis*. *Clin Nucl Med*, 2000. **25**(4): p. 249-52.
92. Wu, C., et al., *Two cases of bacterial suppurative thyroiditis caused by Streptococcus anginosus*. *Endocr Pathol*, 2013. **24**(1): p. 49-53.
93. Miyauchi, A., et al., *Evaluation of chemocauterization treatment for obliteration of pyriform sinus fistula as a route of infection causing acute suppurative thyroiditis*. *Thyroid*, 2009. **19**(7): p. 789-93.
94. Nishihara, E., et al., *Clinical characteristics of 852 patients with subacute thyroiditis before treatment*. *Intern Med*, 2008. **47**(8): p. 725-9.
95. Hong, J.T., et al., *Case of concurrent Riedel's thyroiditis, acute suppurative thyroiditis, and micropapillary carcinoma*. *Korean J Intern Med*, 2013. **28**(2): p. 236-41.
96. Miyauchi, A., *Thyroid gland: A new management algorithm for acute suppurative thyroiditis?* *Nat Rev Endocrinol*, 2010. **6**(8): p. 424-6.
97. Kim, S., et al., *Subacute painful thyroiditis accompanied by scrub typhus infection*. *Endocrine*, 2013. **44**(2): p. 546-8.
98. Masuoka, H., et al., *Imaging studies in sixty patients with acute suppurative thyroiditis*. *Thyroid*, 2011. **21**(10): p. 1075-80.
99. Ruchala, M., et al., *The role of sonoelastography in acute, subacute and chronic thyroiditis - a novel application of the method*. *Eur J Endocrinol*, 2011.
100. Bernard, P.J., et al., *The CT findings of acute thyroiditis and acute suppurative thyroiditis*. *Otolaryngol Head Neck Surg*, 1988. **99**(5): p. 489-93.
101. Yung, G., et al., *Riedel thyroiditis demonstrated on gallium scintigraphy*. *Clin Nucl Med*, 2010. **35**(8): p. 614-7.
102. Park, N.H., et al., *The emerging echogenic tract sign of pyriform sinus fistula: an early indicator in the recovery stage of acute suppurative thyroiditis*. *AJNR Am J Neuroradiol*, 2011. **32**(3): p. E44-6.
103. Miyauchi, A., et al., *Computed tomography scan under a trumpet maneuver to demonstrate pyriform sinus fistulae in patients with acute suppurative thyroiditis*. *Thyroid*, 2005. **15**(12): p. 1409-13.
104. Ukiyama, E., et al., *Light guided procedure for congenital pyriform sinus fistula; new and simple procedure for impalpable fistula*. *Pediatr Surg Int*, 2007. **23**(12): p. 1241-3.
105. Kim, K.H., et al., *Pyriform sinus fistula: management with chemocauterization of the internal opening*. *Ann Otol Rhinol Laryngol*, 2000. **109**(5): p. 452-6.
106. Smith, S.L. and K.D. Pereira, *Suppurative thyroiditis in children: a management algorithm*. *Pediatr Emerg Care*, 2008. **24**(11): p. 764-7.
107. Pereira, K.D. and S.L. Smith, *Endoscopic chemical cautery of pyriform sinus tracts: a safe new technique*. *Int J Pediatr Otorhinolaryngol*, 2008. **72**(2): p. 185-8.

108. Jordan, J.A., et al., *Endoscopic cauterization for treatment of fourth branchial cleft sinuses*. Arch Otolaryngol Head Neck Surg, 1998. **124**(9): p. 1021-4.
109. Rauhofer, U., et al., *Cystic echinococcosis of the thyroid gland in children and adults*. Thyroid, 2003. **13**(5): p. 497-502.
110. Mordes, D.A. and E.F. Brachtel, *Cytopathology of subacute thyroiditis*. Diagn Cytopathol, 2011.
111. Pereira, K.D., et al., *Management of anomalies of the third and fourth branchial pouches*. Int J Pediatr Otorhinolaryngol, 2004. **68**(1): p. 43-50.
112. Nicoucar, K., et al., *Management of congenital third branchial arch anomalies: a systematic review*. Otolaryngol Head Neck Surg, 2010. **142**(1): p. 21-28 e2.
113. Kruijff, S., et al., *Thyroidal abscesses in third and fourth branchial anomalies: not only a paediatric diagnosis*. ANZ J Surg, 2014.
114. Kamide, D., et al., *Minimally invasive surgery for pyriform sinus fistula by transoral videolaryngoscopic surgery*. Am J Otolaryngol, 2015. **36**(4): p. 601-5.
115. Xiao, X., et al., *Endoscopic-assisted surgery for pyriform sinus fistula in children: experience of 165 cases from a single institution*. J Pediatr Surg, 2014. **49**(4): p. 618-21.
116. Volpe, R., *The management of subacute (DeQuervain's) thyroiditis*. Thyroid, 1993. **3**(3): p. 253-5.
117. Ogawa, E., et al., *Subacute thyroiditis in children: patient report and review of the literature*. J Pediatr Endocrinol Metab, 2003. **16**(6): p. 897-900.
118. Tamai, H., et al., *The incidence of thyroid stimulating blocking antibodies during the hypothyroid phase in patients with subacute thyroiditis*. J Clin Endocrinol Metab, 1991. **73**(2): p. 245-50.
119. Galluzzo, A., et al., *Leukocyte migration test in subacute thyroiditis: hypothetical role of cell-mediated immunity*. J Clin Endocrinol Metab, 1980. **50**(6): p. 1038-41.
120. Parmar, R.C., et al., *Thyroiditis as a presenting feature of mumps*. Pediatr Infect Dis J, 2001. **20**(6): p. 637-8.
121. Dimos, G., G. Pappas, and N. Akritidis, *Subacute thyroiditis in the course of novel H1N1 influenza infection*. Endocrine, 2010. **37**(3): p. 440-1.
122. Volta, C., et al., *Atypical subacute thyroiditis caused by Epstein-Barr virus infection in a three-year-old girl*. Thyroid, 2005. **15**(10): p. 1189-91.
123. Bouillet, B., et al., *A case of subacute thyroiditis associated with primary HIV infection*. Am J Med, 2009. **122**(4): p. e5-6.
124. Satoh, M., *Virus-like particles in the follicular epithelium of the thyroid from a patient with subacute thyroiditis (deQuervain's)*. Acta Pathol Jpn, 1975. **25**: p. 499-501.
125. Engkakul, P., P. Mahachoklertwattana, and P. Poomthavorn, *de Quervain thyroiditis in a young boy following hand-foot-mouth disease*. Eur J Pediatr, 2011. **170**(4): p. 527-9.
126. Luotola, K., et al., *Evaluation of infectious etiology in subacute thyroiditis--lack of association with coxsackievirus infection*. APMIS, 1998. **106**(4): p. 500-4.
127. Mori, K., et al., *Failure in detection of Epstein-Barr virus and cytomegalovirus in specimen obtained by fine needle aspiration biopsy of thyroid in patients with subacute thyroiditis*. Tohoku J Exp Med, 1998. **186**(1): p. 13-7.
128. Espino Montoro, A., et al., *[Subacute thyroiditis associated with positive antibodies to the Epstein-Barr virus]*. An Med Interna, 2000. **17**(10): p. 546-8.

129. Al Maawali, A., S. Al Yaarubi, and A. Al Futaisi, *An infant with cytomegalovirus-induced subacute thyroiditis*. J Pediatr Endocrinol Metab, 2008. **21**(2): p. 191-3.
130. Desailoud, R. and D. Hober, *Viruses and thyroiditis: an update*. Virol J, 2009. **6**: p. 5.
131. Buc, M., et al., *HLA-BW35 and subacute de Quervain's thyroiditis [proceedings]*. Diabete Metab, 1976. **2**(3): p. 163.
132. Hamaguchi, E., et al., *Subacute thyroiditis developed in identical twins two years apart*. Endocr J, 2005. **52**(5): p. 559-62.
133. Kabalak, T. and A.G. Ozgen, *Familial occurrence of subacute thyroiditis*. Endocr J, 2002. **49**(2): p. 207-9.
134. Zein, E.F., S.E. Karaa, and A. Megarbane, *Familial occurrence of painful subacute thyroiditis associated with human leukocyte antigen-B35*. Presse Med, 2007. **36**(5 Pt 1): p. 808-9.
135. Kramer, A.B., C. Roozendaal, and R.P. Dullaart, *Familial occurrence of subacute thyroiditis associated with human leukocyte antigen-B35*. Thyroid, 2004. **14**(7): p. 544-7.
136. Kalmus, Y., et al., *Sweet's syndrome and subacute thyroiditis*. Postgrad Med J, 2000. **76**(894): p. 229-30.
137. Richard, J., et al., *Sweet's syndrome and subacute thyroiditis: an unrecognized association?* Thyroid, 2010. **20**(12): p. 1425-6.
138. Vassilopoulou-Sellin, R., et al., *Acute thyroid dysfunction (thyroiditis) after therapy with interleukin-2*. Horm Metab Res, 1992. **24**(9): p. 434-8.
139. Amenomori, M., et al., *Incidence and characteristics of thyroid dysfunction following interferon therapy in patients with chronic hepatitis C*. Intern Med, 1998. **37**(3): p. 246-52.
140. Orlov, S., et al., *Induction of painless thyroiditis in patients receiving programmed death 1 receptor immunotherapy for metastatic malignancies*. J Clin Endocrinol Metab, 2015. **100**(5): p. 1738-41.
141. Hernan Martinez, J., et al., *Subacute thyroiditis and dyserythropoiesis after influenza vaccination suggesting immune dysregulation*. Bol Asoc Med P R, 2011. **103**(2): p. 48-52.
142. Hsiao, J.Y., et al., *Subacute thyroiditis following influenza vaccine (Vaxigrip) in a young female*. Kaohsiung J Med Sci, 2006. **22**(6): p. 297-300.
143. Shen, L., et al., *Thyroid dysfunction during interferon alpha therapy for chronic hepatitis C*. Clin Nucl Med, 2005. **30**(8): p. 546-7.
144. Kryczka, W., et al., *Thyroid gland dysfunctions during antiviral therapy of chronic hepatitis C*. Med Sci Monit, 2001. **7 Suppl 1**: p. 221-5.
145. Parana, R., et al., *Subacute thyroiditis during treatment with combination therapy (interferon plus ribavirin) for hepatitis C virus*. J Viral Hepat, 2000. **7**(5): p. 393-5.
146. Omur, O., et al., *Subacute thyroiditis during interferon therapy for chronic hepatitis B infection*. Clin Nucl Med, 2003. **28**(10): p. 864-5.
147. Moser, C., J. Furrer, and F. Ruggieri, *[Neck pain and fever after peginterferon alpha-2a]*. Praxis (Bern 1994), 2007. **96**(6): p. 205-7.
148. Ohta, Y., et al., *Inflammatory diseases associated with Takayasu's arteritis*. Angiology, 2003. **54**(3): p. 339-44.

149. Obuobie, K., A. Al-Sabah, and J.H. Lazarus, *Subacute thyroiditis in an immunosuppressed patient*. J Endocrinol Invest, 2002. **25**(2): p. 169-71.
150. Ozdogu, H., et al., *Wegener's granulomatosis with a possible thyroidal involvement*. J Natl Med Assoc, 2006. **98**(6): p. 956-8.
151. Daniels, G.H., et al., *Alemtuzumab-related thyroid dysfunction in a phase 2 trial of patients with relapsing-remitting multiple sclerosis*. J Clin Endocrinol Metab, 2014. **99**(1): p. 80-9.
152. Algun, E., et al., *Coexistence of subacute thyroiditis and renal cell carcinoma: a paraneoplastic syndrome*. CMAJ, 2003. **168**(8): p. 985-6.
153. Calvi, L. and G.H. Daniels, *Acute thyrotoxicosis secondary to destructive thyroiditis associated with cardiac catheterization contrast dye*. Thyroid, 2011. **21**(4): p. 443-9.
154. Carneiro, J.R., R.G. Macedo, and V.G. Da Silveira, *Thyrotoxicosis after gastric bypass*. Obes Surg, 2004. **14**(5): p. 699-701.
155. Sanavi, S. and R. Afshar, *Subacute thyroiditis following ginger (Zingiber officinale) consumption*. Int J Ayurveda Res, 2010. **1**(1): p. 47-8.
156. Chang, T.C., et al., *Three-dimensional cytomorphology in fine needle aspiration biopsy of subacute thyroiditis*. Acta Cytol, 2004. **48**(2): p. 155-60.
157. Woolner, L.B., C.W. Mc, and O.H. Beahrs, *Granulomatous thyroiditis (De Quervain's thyroiditis)*. J Clin Endocrinol Metab, 1957. **17**(10): p. 1202-21.
158. Koga, M., et al., *Immunohistochemical analysis of Bcl-2, Bax, and Bak expression in thyroid glands from patients with subacute thyroiditis*. J Clin Endocrinol Metab, 1999. **84**(6): p. 2221-5.
159. Toda, S., et al., *Immunohistochemical expression of growth factors in subacute thyroiditis and their effects on thyroid folliculogenesis and angiogenesis in collagen gel matrix culture*. J Pathol, 1999. **188**(4): p. 415-22.
160. Luotola, K., et al., *Allele 2 of interleukin-1 receptor antagonist gene increases the risk of thyroid peroxidase antibodies in subacute thyroiditis*. APMIS, 2001. **109**(6): p. 454-60.
161. Chen, K., et al., *Decreasing TNF-alpha results in less fibrosis and earlier resolution of granulomatous experimental autoimmune thyroiditis*. J Leukoc Biol, 2007. **81**(1): p. 306-14.
162. Fang, Y., et al., *A critical role for TRAIL in resolution of granulomatous experimental autoimmune thyroiditis*. J Pathol, 2008. **216**(4): p. 505-13.
163. Toda, S., et al., *Growth factor-expressing mast cells accumulate at the thyroid tissue-regenerative site of subacute thyroiditis*. Thyroid, 2000. **10**(5): p. 381-6.
164. Greene, J.N., *Subacute thyroiditis*. Am J Med, 1971. **51**(1): p. 97-108.
165. Carle, A., et al., *Epidemiology of subtypes of hypothyroidism in Denmark*. Eur J Endocrinol, 2006. **154**(1): p. 21-8.
166. Fatourechi, V., et al., *Clinical features and outcome of subacute thyroiditis in an incidence cohort: Olmsted County, Minnesota, study*. J Clin Endocrinol Metab, 2003. **88**(5): p. 2100-5.
167. Qari, F.A. and A.A. Maimani, *Subacute thyroiditis in Western Saudi Arabia*. Saudi Med J, 2005. **26**(4): p. 630-3.

168. Anastasilakis, A.D., et al., *A case report of subacute thyroiditis during pregnancy: difficulties in differential diagnosis and changes in cytokine levels*. Gynecol Endocrinol, 2011. **27**(6): p. 384-90.
169. Hiraiwa, T., et al., *Two cases of subacute thyroiditis presenting in pregnancy*. J Endocrinol Invest, 2006. **29**(10): p. 924-7.
170. Daniels, G.H., *Atypical subacute thyroiditis: preliminary observations*. Thyroid, 2001. **11**(7): p. 691-5.
171. Dedititis, R.A. and L.S. Coelho, *Vocal fold paralysis in subacute thyroiditis*. Braz J Otorhinolaryngol, 2007. **73**(1): p. 138.
172. Nakamura, S., Y. Saio, and M. Ishimori, *Recurrent hemithyroiditis: a case report*. Endocr J, 1998. **45**(4): p. 595-600.
173. Sari, O., B. Erbas, and T. Erbas, *Subacute thyroiditis in a single lobe*. Clin Nucl Med, 2001. **26**(5): p. 400-1.
174. Alper, A.T., et al., *Incessant ventricular tachycardia due to subacute thyroiditis*. Int J Cardiol, 2007. **116**(1): p. e22-4.
175. Sherman, S.I., L. Simonson, and P.W. Ladenson, *Clinical and socioeconomic predispositions to complicated thyrotoxicosis: a predictable and preventable syndrome?* Am J Med, 1996. **101**(2): p. 192-8.
176. Swinburne, J.L. and S.H. Kreisman, *A rare case of subacute thyroiditis causing thyroid storm*. Thyroid, 2007. **17**(1): p. 73-6.
177. Kim, H.J., et al., *Thyrotoxicosis-induced acute myocardial infarction due to painless thyroiditis*. Thyroid, 2011. **21**(10): p. 1149-51.
178. Mizokami, T., et al., *Localized painful giant-cell thyroiditis without inflammatory signs in a euthyroid patient followed by serial sonography*. J Clin Ultrasound, 1998. **26**(6): p. 329-32.
179. Cunha, B.A., A. Chak, and S. Stollo, *Fever of unknown origin (FUO): de Quervain's subacute thyroiditis with highly elevated ferritin levels mimicking temporal arteritis (TA)*. Heart Lung, 2010. **39**(1): p. 73-7.
180. Benbassat, C.A., et al., *Subacute thyroiditis: clinical characteristics and treatment outcome in fifty-six consecutive patients diagnosed between 1999 and 2005*. J Endocrinol Invest, 2007. **30**(8): p. 631-5.
181. Matsumoto, Y., et al., *Serial changes in liver function tests in patients with subacute thyroiditis*. Thyroid, 2008. **18**(7): p. 815-6.
182. Fragu, P., et al., *Evolution of thyroid 127I stores measured by X-ray fluorescence in subacute thyroiditis*. J Clin Endocrinol Metab, 1982. **54**(1): p. 162-6.
183. Gordin, A. and B.A. Lamberg, *Serum thyrotrophin response to thyrotrophin releasing hormone and the concentration of free thyroxine in subacute thyroiditis*. Acta Endocrinol (Copenh), 1973. **74**(1): p. 111-21.
184. Intenzo, C.M., et al., *Clinical, laboratory, and scintigraphic manifestations of subacute and chronic thyroiditis*. Clin Nucl Med, 1993. **18**(4): p. 302-6.
185. Rapoport, B., et al., *Depletion of thyroid iodine during subacute thyroiditis*. J Clin Endocrinol Metab, 1973. **36**(3): p. 610-1.
186. Savoie, J.C., et al., *Iodine-induced thyrotoxicosis in apparently normal thyroid glands*. J Clin Endocrinol Metab, 1975. **41**(4): p. 685-91.

187. Woolf, P.D., *Transient painless thyroiditis with hyperthyroidism: a variant of lymphocytic thyroiditis?* Endocr Rev, 1980. **1**(4): p. 411-20.
188. Pearce, E.N., et al., *The prevalence of elevated serum C-reactive protein levels in inflammatory and noninflammatory thyroid disease.* Thyroid, 2003. **13**(7): p. 643-8.
189. Rao, N.L., et al., *Salivary C-Reactive Protein in Hashimoto's Thyroiditis and Subacute Thyroiditis.* Int J Inflam, 2010. **2010**: p. 514659.
190. Fujii, S., et al., *Subacute thyroiditis with highly positive thyrotropin receptor antibodies and high thyroidal radioactive iodine uptake.* Intern Med, 2003. **42**(8): p. 704-9.
191. Iitaka, M., et al., *TSH receptor antibody-associated thyroid dysfunction following subacute thyroiditis.* Clin Endocrinol (Oxf), 1998. **48**(4): p. 445-53.
192. Kamijo, K., *TSH-receptor antibody measurement in patients with various thyrotoxicosis and Hashimoto's thyroiditis: a comparison of two two-step assays, coated plate ELISA using porcine TSH-receptor and coated tube radioassay using human recombinant TSH-receptor.* Endocr J, 2003. **50**(1): p. 113-6.
193. Takasu, N., et al., *Sensitive thyroid-stimulating antibody assay with high concentrations of polyethylene glycol for the diagnosis of Graves' disease.* Clin Exp Pharmacol Physiol, 2004. **31**(5-6): p. 314-9.
194. Hiromatsu, Y., et al., *Technetium-99m tetrofosmin imaging in patients with subacute thyroiditis.* Eur J Nucl Med, 1998. **25**(10): p. 1448-52.
195. Hiromatsu, Y., et al., *Technetium-99 m sestamibi imaging in patients with subacute thyroiditis.* Endocr J, 2003. **50**(3): p. 239-44.
196. Alonso, O., et al., *99Tc(m)-MIBI scanning of the thyroid gland in patients with markedly decreased pertechnetate uptake.* Nucl Med Commun, 1998. **19**(3): p. 257-61.
197. Janssen, O.E., *[Atypical presentation of subacute thyroiditis].* Dtsch Med Wochenschr, 2011. **136**(11): p. 519-22.
198. Song, Y.S., et al., *F-18 fluorodeoxyglucose (FDG) positron emission tomography (PET) and Tc-99m pertechnate scan findings of a patient with unilateral subacute thyroiditis.* Clin Nucl Med, 2009. **34**(7): p. 456-8.
199. Kunz, A., W. Blank, and B. Braun, *De Quervain's subacute thyroiditis -- colour Doppler sonography findings.* Ultraschall Med, 2005. **26**(2): p. 102-6.
200. Park, S.Y., et al., *Ultrasonographic characteristics of subacute granulomatous thyroiditis.* Korean J Radiol, 2006. **7**(4): p. 229-34.
201. Omori, N., K. Omori, and K. Takano, *Association of the ultrasonographic findings of subacute thyroiditis with thyroid pain and laboratory findings.* Endocr J, 2008. **55**(3): p. 583-8.
202. Cappelli, C., et al., *Ultrasound findings of subacute thyroiditis: a single institution retrospective review.* Acta Radiol, 2014. **55**(4): p. 429-33.
203. Nishihara, E., et al., *Papillary carcinoma obscured by complication with subacute thyroiditis: sequential ultrasonographic and histopathological findings in five cases.* Thyroid, 2008. **18**(11): p. 1221-5.
204. Tezuka, M., et al., *MR imaging of the thyroid: correlation between apparent diffusion coefficient and thyroid gland scintigraphy.* J Magn Reson Imaging, 2003. **17**(2): p. 163-9.

205. Yeo, S.H., et al., *Subacute thyroiditis presenting as a focal lesion on [18F] fluorodeoxyglucose whole-body positron-emission tomography/CT*. AJNR Am J Neuroradiol, 2011. **32**(4): p. E58-60.
206. Shabb, N.S. and I. Salti, *Subacute thyroiditis: fine-needle aspiration cytology of 14 cases presenting with thyroid nodules*. Diagn Cytopathol, 2006. **34**(1): p. 18-23.
207. Ito, M., et al., *Incomplete thyrotroph suppression determined by third generation thyrotropin assay in subacute thyroiditis compared to silent thyroiditis or hyperthyroid Graves' disease*. J Clin Endocrinol Metab, 1997. **82**(2): p. 616-9.
208. Vierhapper, H., et al., *Normal serum concentrations of sex hormone binding-globulin in patients with hyperthyroidism due to subacute thyroiditis*. Thyroid, 1998. **8**(12): p. 1107-11.
209. Nakano, Y., H. Kurihara, and J. Sasaki, *Graves' disease following subacute thyroiditis*. Tohoku J Exp Med, 2011. **225**(4): p. 301-9.
210. Tesfaye, H., et al., *Subacute thyroiditis confused with dental problem*. Cas Lek Cesk, 2009. **148**(9): p. 438-41.
211. Meller, J., C.O. Sahlmann, and A.K. Scheel, *18F-FDG PET and PET/CT in fever of unknown origin*. J Nucl Med, 2007. **48**(1): p. 35-45.
212. Yasuda, S., et al., *Chronic thyroiditis: diffuse uptake of FDG at PET*. Radiology, 1998. **207**(3): p. 775-8.
213. Liel, Y., *The survivor: association of an autonomously functioning thyroid nodule and subacute thyroiditis*. Thyroid, 2007. **17**(2): p. 183-4.
214. King, D.L., et al., *Incidence of thyroid carcinoma in fluorodeoxyglucose positron emission tomography-positive thyroid incidentalomas*. Otolaryngol Head Neck Surg, 2007. **137**(3): p. 400-4.
215. Van den Bruel, A., et al., *Clinical relevance of thyroid fluorodeoxyglucose-whole body positron emission tomography incidentaloma*. J Clin Endocrinol Metab, 2002. **87**(4): p. 1517-20.
216. Zacharia, T.T., et al., *Gray-scale and color Doppler sonographic findings in a case of subacute granulomatous thyroiditis mimicking thyroid carcinoma*. J Clin Ultrasound, 2002. **30**(7): p. 442-4.
217. Xie, P., Y. Xiao, and F. Liu, *Real-time ultrasound elastography in the diagnosis and differential diagnosis of subacute thyroiditis*. J Clin Ultrasound, 2011. **39**(8): p. 435-40.
218. Kubota, S., et al., *Initial treatment with 15 mg of prednisolone daily is sufficient for most patients with subacute thyroiditis in Japan*. Thyroid, 2013. **23**(3): p. 269-72.
219. Ma, S.G., F. Bai, and L. Cheng, *A novel treatment for subacute thyroiditis: administration of a mixture of lidocaine and dexamethasone using an insulin pen*. Mayo Clin Proc, 2014. **89**(6): p. 861-2.
220. Martinez, D.S. and I.J. Chopra, *Use of oral cholecystography agents in the treatment of hyperthyroidism of subacute thyroiditis*. Panminerva Med, 2003. **45**(1): p. 53-7.
221. Mizukoshi, T., et al., *Evaluation of recurrence in 36 subacute thyroiditis patients managed with prednisolone*. Intern Med, 2001. **40**(4): p. 292-5.
222. Duinink, T.M., et al., *de Quervain's thyroiditis: surgical experience*. Endocr Pract, 2002. **8**(4): p. 255-8.

223. Iitaka, M., et al., *Incidence of subacute thyroiditis recurrences after a prolonged latency: 24-year survey*. J Clin Endocrinol Metab, 1996. **81**(2): p. 466-9.
224. Nishihara, E., et al., *Extent of hypoechogenic area in the thyroid is related with thyroid dysfunction after subacute thyroiditis*. J Endocrinol Invest, 2009. **32**(1): p. 33-6.
225. Bogazzi, F., et al., *Long-term outcome of thyroid function after amiodarone-induced thyrotoxicosis, as compared to subacute thyroiditis*. J Endocrinol Invest, 2006. **29**(8): p. 694-9.
226. Izumi, M. and P.R. Larsen, *Correlation of sequential changes in serum thyroglobulin, triiodothyronine, and thyroxine in patients with Graves' disease and subacute thyroiditis*. Metabolism, 1978. **27**(4): p. 449-60.
227. Goodman, H.I., *Riedel's Thyroiditis: a review and report of two cases*. American Journal of Surgery, 1941. **54**(2): p. 472-478.
228. Riedel, B.M., *Die chronische zur Bildung eisenharter Tumoren fuehrende Entzuendung der Schilddruese*. Verh Ges Chir., 1896. **25**: p. 101-105.
229. Riedel, B.M., *Vorstellung eines Kranken mit chronischer Strumitis*. Verh Ges Chir., 1896. **26**: p. 127-129.
230. Riedel, B.M., *Ueber Verlauf und Ausgang der chronischer Strumitis*. Munch Med Wochenschr, 1910. **57**: p. 1946-1947.
231. de Lange, W.E., et al., *Invasive fibrous thyroiditis (Riedel's struma): a manifestation of multifocal fibrosclerosis? A case report with review of the literature*. Q J Med, 1989. **72**(268): p. 709-17.
232. Zimmermann-Belsing, T. and U. Feldt-Rasmussen, *Riedel's thyroiditis: an autoimmune or primary fibrotic disease?* J Intern Med, 1994. **235**(3): p. 271-4.
233. Hay, I.D., *Thyroiditis: a clinical update*. Mayo Clin Proc, 1985. **60**(12): p. 836-43.
234. Guimaraes, V.C., *Subacute and Reidel's Thyroiditis*, in *Endocrinology: Adult and Pediatric*, J.L. Jameson and L.J. De Groot, Editors. 2010, Elsevier: Philadelphia. p. 1600-1603.
235. Fatourechi, M.M., et al., *Invasive fibrous thyroiditis (riedel thyroiditis): the mayo clinic experience, 1976-2008*. Thyroid, 2011. **21**(7): p. 765-72.
236. Hennessey, J.V., *Clinical review: Riedel's thyroiditis: a clinical review*. J Clin Endocrinol Metab, 2011. **96**(10): p. 3031-41.
237. Balach, Z.W. and V.A. LiVolsi, *Pathology*, in *Werner & Ingbar's The Thyroid; A Fundamental and Clinical Text*, L.E. Braverman and R.E. Utiger, Editors. 2005, Lippincott Williams & Wilkins: Philadelphia. p. 427.
238. Lee, S.L. and S. Ananthakrishnan, *Infiltrative thyroid disease*, in *UpToDate*, B.D. Rose and J.E. Mulder, Editors. 2011, BDR, Inc.: Wellesley, MA. p. 1-21.
239. Heufelder, A.E., et al., *Tissue eosinophilia and eosinophil degranulation in Riedel's invasive fibrous thyroiditis*. J Clin Endocrinol Metab, 1996. **81**(3): p. 977-84.
240. Volpe, R., *Subacute and Sclerosing Thyroiditis*, in *Endocrinology*, L.J. De Groot, Editor. 1995, WB Saunders: Philadelphia. p. 742-751.
241. Schwaegerle, S.M., T.W. Bauer, and C.B. Esselstyn, Jr., *Riedel's thyroiditis*. Am J Clin Pathol, 1988. **90**(6): p. 715-22.
242. Beahrs, O.H., W.M. McConahey, and L.B. Woolner, *Invasive fibrous thyroiditis (Riedel's struma)*. J Clin Endocrinol Metab, 1957. **17**(2): p. 201-20.

243. Torres-Montaner, A., et al., *Sarcoma of the thyroid region mimicking Riedel's thyroiditis*. J Clin Pathol, 2001. **54**(7): p. 570-2.
244. Wan, S.K., J.K. Chan, and S.K. Tang, *Paucicellular variant of anaplastic thyroid carcinoma. A mimic of Reidel's thyroiditis*. Am J Clin Pathol, 1996. **105**(4): p. 388-93.
245. Katsikas, D., A.J. Shorthouse, and S. Taylor, *Riedel's thyroiditis*. Br J Surg, 1976. **63**(12): p. 929-31.
246. LiVolsi, V.A. and P. LoGerfo, eds. *Thyroiditis*. 1981, CRC Press: Boca Raton. 21-42.
247. Cho, M.H., et al., *Riedel's thyroiditis in a patient with recurrent subacute thyroiditis: a case report and review of the literature*. Endocr J, 2007. **54**(4): p. 559-62.
248. Pirola, I., et al., *A Case of Concurrent Riedel's, Hashimoto's and Acute Suppurative Thyroiditis*. Case Report Med, 2009. **2009**: p. 535974.
249. McIver, B., et al., *Graves' disease after unilateral Riedel's thyroiditis*. J Clin Endocrinol Metab, 2010. **95**(6): p. 2525-6.
250. Kojima, M., et al., *Riedel's thyroiditis containing cytologically atypically appearing B-cells: a case report*. Pathol Res Pract, 2003. **199**(7): p. 497-501.
251. Chen, K., et al., *Characterization of thyroid fibrosis in a murine model of granulomatous experimental autoimmune thyroiditis*. J Leukoc Biol, 2000. **68**(6): p. 828-35.
252. Li, Y., et al., *Immunohistochemistry of IgG4 can help subclassify Hashimoto's autoimmune thyroiditis*. Pathol Int, 2009. **59**(9): p. 636-41.
253. Neild, G.H., et al., *Hyper-IgG4 disease: report and characterisation of a new disease*. BMC Med, 2006. **4**: p. 23.
254. Dahlgren, M., et al., *Riedel's thyroiditis and multifocal fibrosclerosis are part of the IgG4-related systemic disease spectrum*. Arthritis Care Res (Hoboken), 2010. **62**(9): p. 1312-8.
255. Yamamoto, M., H. Takahashi, and Y. Shinomura, *[IgG4-related systemic disease/systemic IgG4-related disease]*. Rinsho Byori, 2010. **58**(5): p. 454-65.
256. Sarles, H., et al., *Chronic inflammatory sclerosis of the pancreas--an autonomous pancreatic disease?* Am J Dig Dis, 1961. **6**: p. 688-98.
257. Hamano, H., et al., *High serum IgG4 concentrations in patients with sclerosing pancreatitis*. N Engl J Med, 2001. **344**(10): p. 732-8.
258. Umehara, H., et al., *Comprehensive diagnostic criteria for IgG4-related disease (IgG4-RD), 2011*. Mod Rheumatol, 2012. **22**(1): p. 21-30.
259. Umehara, H., et al., *A novel clinical entity, IgG4-related disease (IgG4RD): general concept and details*. Mod Rheumatol, 2012. **22**(1): p. 1-14.
260. Palazzo, E., C. Palazzo, and M. Palazzo, *IgG4-related disease*. Joint Bone Spine, 2014. **81**(1): p. 27-31.
261. Deshpande, V., et al., *Consensus statement on the pathology of IgG4-related disease*. Mod Pathol, 2012. **25**(9): p. 1181-92.
262. Takeshima, K., et al., *Clinicopathological features of Riedel's thyroiditis associated with IgG4-related disease in Japan*. Endocr J, 2015.
263. Pusztaszeri, M., et al., *Riedel's thyroiditis with increased IgG4 plasma cells: evidence for an underlying IgG4-related sclerosing disease?* Thyroid, 2012. **22**(9): p. 964-8.
264. Soh, S.B., et al., *Novel use of rituximab in a case of Riedel's thyroiditis refractory to glucocorticoids and tamoxifen*. J Clin Endocrinol Metab, 2013. **98**(9): p. 3543-9.

265. Oriot, P., et al., *Fibrosis of the thyroid gland caused by an IgG4-related sclerosing disease: three years of follow-up*. Acta Clin Belg, 2014. **69**(6): p. 446-50.
266. Ghys, C., et al., *Cervical lymph nodes, thyroiditis and ophthalmopathy: the pleomorphic face of an immunoglobulin g4-related disease*. Eur Thyroid J, 2014. **3**(4): p. 252-7.
267. Pearce, E.N., A.P. Farwell, and L.E. Braverman, *Thyroiditis*. N Engl J Med, 2003. **348**(26): p. 2646-55.
268. Lu, L., et al., *Clinical and pathological features of Riedel's thyroiditis*. Chin Med Sci J, 2010. **25**(3): p. 129-34.
269. Annaert, M., et al., *Riedel's thyroiditis occurring in a multinodular goiter, mimicking thyroid cancer*. J Clin Endocrinol Metab, 2007. **92**(6): p. 2005-6.
270. Vigouroux, C., et al., *[Riedel's thyroiditis and lymphoma. Diagnostic difficulties]*. Presse Med, 1996. **25**(1): p. 28-30.
271. Sheu, S.Y. and K.W. Schmid, *[Inflammatory diseases of the thyroid gland. Epidemiology, symptoms and morphology]*. Pathologe, 2003. **24**(5): p. 339-47.
272. Ozgur, T., et al., *A case of asymptomatic riedel thyroiditis with follicular adenoma in a patient with a multinodular goiter: an unusual association*. Eur Thyroid J, 2012. **1**(3): p. 204-7.
273. Shahi, N., et al., *Riedel's thyroiditis masquerading as anaplastic thyroid carcinoma: a case report*. J Med Case Reports, 2010. **4**: p. 15.
274. Kumar, S.S., et al., *Atypical Presentation of Riedel's Thyroiditis: Multifocal Nodular Fibrosis and Resolution with Levothyroxine*. Eur Thyroid J, 2012. **1**(4): p. 259-63.
275. Best, T.B., et al., *Riedel's thyroiditis associated with Hashimoto's thyroiditis, hypoparathyroidism, and retroperitoneal fibrosis*. J Endocrinol Invest, 1991. **14**(9): p. 767-72.
276. Chopra, D., et al., *Riedel's struma associated with subacute thyroiditis, hypothyroidism, and hypoparathyroidism*. J Clin Endocrinol Metab, 1978. **46**(6): p. 869-71.
277. Marin, F., et al., *Riedel's thyroiditis associated with hypothyroidism and hypoparathyroidism*. Postgrad Med J, 1989. **65**(764): p. 381-3.
278. Yasmeen, T., et al., *Clinical case seminar: Riedel's thyroiditis: report of a case complicated by spontaneous hypoparathyroidism, recurrent laryngeal nerve injury, and Horner's syndrome*. J Clin Endocrinol Metab, 2002. **87**(8): p. 3543-7.
279. Nazal, E.M., et al., *Hypoparathyroidism preceding Riedel's thyroiditis*. Eur J Intern Med, 2003. **14**(3): p. 202-204.
280. Stan, M.N., E.G. Haglind, and M.T. Drake, *Early Hypoparathyroidism Reversibility with Treatment of Riedel's Thyroiditis*. Thyroid, 2015. **25**(9): p. 1055-9.
281. Heufelder, A.E. and I.D. Hay, *Further evidence for autoimmune mechanisms in the pathogenesis of Riedel's invasive fibrous thyroiditis*. J Intern Med, 1995. **238**(1): p. 85-6.
282. Heufelder, A.E. and R.S. Bahn, *Modulation of Graves' orbital fibroblast proliferation by cytokines and glucocorticoid receptor agonists*. Invest Ophthalmol Vis Sci, 1994. **35**(1): p. 120-7.
283. Khan, M.A., et al., *Reidel's thyroiditis and Tolosa-Hunt syndrome, a rare association*. J Laryngol Otol, 2004. **118**(2): p. 159-61.
284. Meijer, S., H.F. Hoitsma, and R. Scholtmeijer, *Idiopathic retroperitoneal fibrosis in multifocal fibrosclerosis*. Eur Urol, 1976. **2**(5): p. 258-60.

285. Meyer, S. and R. Hausman, *Occlusive phlebitis in multifocal fibrosclerosis*. Am J Clin Pathol, 1976. **65**(3): p. 274-83.
286. Geissler, B., et al., *Extensive sterile abscess in an invasive fibrous thyroiditis (Riedel's thyroiditis) caused by an occlusive vasculitis*. J Endocrinol Invest, 2001. **24**(2): p. 111-5.
287. Vaidya, B., et al., *Cerebral venous sinus thrombosis: a late sequel of invasive fibrous thyroiditis*. Thyroid, 1998. **8**(9): p. 787-90.
288. Natt, N., et al., *Extracervical fibrosclerosis causing obstruction of a ventriculo-peritoneal shunt in a patient with hydrocephalus and invasive fibrous thyroiditis (Riedel's struma)*. Clin Endocrinol (Oxf), 1997. **47**(1): p. 107-11.
289. Egsgaard Nielsen, V., et al., *A rare case of orbital involvement in Riedel's thyroiditis*. J Endocrinol Invest, 2003. **26**(10): p. 1032-6.
290. Hines, R.C., et al., *Invasive fibrous (Riedel's) thyroiditis with bilateral fibrous parotitis*. JAMA, 1970. **213**(5): p. 869-71.
291. Rao, C.R., G.C. Ferguson, and V.N. Kyle, *Retroperitoneal fibrosis associated with Riedel's struma*. Can Med Assoc J, 1973. **108**(8): p. 1019-21.
292. Julie, C., et al., *Hashimoto's thyroiditis associated with Riedel's thyroiditis and retroperitoneal fibrosis*. Pathol Res Pract, 1997. **193**(8): p. 573-7; discussion 578.
293. Brihaye, B., et al., *Diffuse periarterial involvement in systemic fibrosclerosis with Riedel's thyroiditis, sclerosing cholangitis, and retroperitoneal fibrosis*. Scand J Rheumatol, 2008. **37**(6): p. 490-2.
294. Owen, K., H. Lane, and M.K. Jones, *Multifocal fibrosclerosis: a case of thyroiditis and bilateral lacrimal gland involvement*. Thyroid, 2001. **11**(12): p. 1187-90.
295. Hamed, G., et al., *Inflammatory lesions of the lung, submandibular gland, bile duct and prostate in a patient with IgG4-associated multifocal systemic fibrosclerosis*. Respirology, 2007. **12**(3): p. 455-7.
296. Cooper, D.S., et al., *Revised American Thyroid Association management guidelines for patients with thyroid nodules and differentiated thyroid cancer*. Thyroid, 2009. **19**(11): p. 1167-214.
297. Ozgen, A. and A. Cila, *Riedel's thyroiditis in multifocal fibrosclerosis: CT and MR imaging findings*. AJNR Am J Neuroradiol, 2000. **21**(2): p. 320-1.
298. Papi, G., et al., *Riedel's thyroiditis: clinical, pathological and imaging features*. Int J Clin Pract, 2002. **56**(1): p. 65-7.
299. Slman, R., et al., *Ultrasound, Elastography, and Fluorodeoxyglucose Positron Emission Tomography/Computed Tomography Imaging in Riedel's Thyroiditis: Report of Two Cases*. Thyroid, 2011.
300. Harigopal, M., et al., *Fine-needle aspiration of Riedel's disease: report of a case and review of the literature*. Diagn Cytopathol, 2004. **30**(3): p. 193-7.
301. Iaconi, P., et al., *Proteomic approach used in the diagnosis of Riedel's thyroiditis: a case report*. J Med Case Rep, 2012. **6**: p. 103.
302. Perez Fontan, P.J., et al., *Riedel thyroiditis: US, CT, and MR evaluation*. J Comput Assist Tomogr., 1993. **17**(2): p. 324-5.
303. Lo, J.C., et al., *Riedel's thyroiditis presenting with hypothyroidism and hypoparathyroidism: dramatic response to glucocorticoid and thyroxine therapy*. Clin Endocrinol (Oxf), 1998. **48**(6): p. 815-8.

304. Takahashi, N., et al., *MR findings with dynamic evaluation in Riedel's thyroiditis*. Clin Imaging, 2002. **26**(2): p. 89-91.
305. Drieskens, O., et al., *Riedel's thyroiditis and retroperitoneal fibrosis in multifocal fibrosclerosis: positron emission tomographic findings*. Clin Nucl Med, 2002. **27**(6): p. 413-5.
306. Kotilainen, P., et al., *Positron emission tomography as an aid in the diagnosis and follow-up of Riedel's thyroiditis*. Eur J Intern Med, 2004. **15**(3): p. 186-189.
307. Moulik, P.K., M.S. Al-Jafari, and A.A. Khaleeli, *Steroid responsiveness in a case of Riedel's thyroiditis and retroperitoneal fibrosis*. Int J Clin Pract, 2004. **58**(3): p. 312-5.
308. Papi, G. and V.A. LiVolsi, *Current concepts on Riedel thyroiditis*. Am J Clin Pathol, 2004. **121 Suppl**: p. S50-63.
309. Vaidya, B., et al., *Corticosteroid therapy in Riedel's thyroiditis*. Postgrad Med J, 1997. **73**(866): p. 817-9.
310. Tutuncu, N.B., et al., *Multifocal idiopathic fibrosclerosis manifesting with Riedel's thyroiditis*. Endocr Pract, 2000. **6**(6): p. 447-9.
311. Hostalet, F., D. Hellin, and J.A. Ruiz, *Tumefactive fibroinflammatory lesion of the head and neck treated with steroids: a case report*. Eur Arch Otorhinolaryngol, 2003. **260**(4): p. 229-31.
312. Bagnasco, M., et al., *Fibrous invasive (Riedel's) thyroiditis with critical response to steroid treatment*. J Endocrinol Invest, 1995. **18**(4): p. 305-7.
313. Thomson, J.A., I.M. Jackson, and W.P. Duguid, *The effect of steroid therapy on Riedel's thyroiditis*. Scott Med J, 1968. **13**(1): p. 13-6.
314. Rodriguez, I., et al., *Solitary fibrous tumor of the thyroid gland: report of seven cases*. Am J Surg Pathol, 2001. **25**(11): p. 1424-8.
315. Few, J., et al., *Riedel's thyroiditis: treatment with tamoxifen*. Surgery, 1996. **120**(6): p. 993-8; discussion 998-9.
316. Levy, J.M., et al., *Combined mycophenolate mofetil and prednisone therapy in tamoxifen- and prednisone-resistant Riedel's thyroiditis*. Thyroid, 2010. **20**(1): p. 105-7.
317. De, M., A. Jaap, and J. Dempster, *Tamoxifen therapy in steroid-resistant Riedel's disease*. Scott Med J, 2002. **47**(1): p. 12-3.
318. Dabelic, N., et al., *Riedel's thyroiditis treated with tamoxifen*. Croat Med J, 2003. **44**(2): p. 239-41.
319. Erdogan, M.F., et al., *A case of Riedel's thyroiditis with pleural and pericardial effusions*. Endocrine, 2009. **35**(3): p. 297-301.
320. Jung, Y.J., et al., *A case of Riedel's thyroiditis treated with tamoxifen: another successful outcome*. Endocr Pract, 2004. **10**(6): p. 483-6.
321. Clark, C.P., D. Vanderpool, and J.T. Preskitt, *The response of retroperitoneal fibrosis to tamoxifen*. Surgery, 1991. **109**(4): p. 502-6.
322. Pritchuk, K., et al., *Tamoxifen therapy for Riedel's thyroiditis*. Laryngoscope, 2004. **114**(10): p. 1758-60.
323. Butta, A., et al., *Induction of transforming growth factor beta 1 in human breast cancer in vivo following tamoxifen treatment*. Cancer Res, 1992. **52**(15): p. 4261-4.
324. Colletta, A.A., et al., *Anti-oestrogens induce the secretion of active transforming growth factor beta from human fetal fibroblasts*. Br J Cancer, 1990. **62**(3): p. 405-9.

325. Arteaga, C.L., et al., *Transforming growth factor beta: potential autocrine growth inhibitor of estrogen receptor-negative human breast cancer cells*. Cancer Res, 1988. **48**(14): p. 3898-904.
326. Hoang, T.D., et al., *Multinodular goiter as the initial presentation of systemic sarcoidosis: limitation of fine-needle biopsy*. Respir Care, 2011. **56**(7): p. 1029-32.
327. Anolik, R.B., et al., *Thyroid dysfunction and cutaneous sarcoidosis*. J Am Acad Dermatol, 2012. **66**(1): p. 167-8.
328. Vailati, A., et al., *Sarcoidosis of the thyroid: report of a case and a review of the literature*. Sarcoidosis, 1993. **10**(1): p. 66-8.
329. Ozdemir, D., S. Dagdelen, and T. Erbas, *Endocrine involvement in systemic amyloidosis*. Endocr Pract, 2010. **16**(6): p. 1056-63.
330. Sethi, Y., et al., *Amyloid goiter: a case of primary thyroid amyloid disease*. Laryngoscope, 2011. **121**(5): p. 961-4.
331. Ozdemir, D., et al., *Amyloid goiter and hypopituitarism in a patient with systemic amyloidosis*. Amyloid, 2011. **18**(1): p. 32-4.
332. Kazdaghli Lagha, E., et al., *Amyloid goiter: first manifestation of systemic amyloidosis*. Eur Ann Otorhinolaryngol Head Neck Dis, 2010. **127**(3): p. 108-10.
333. Vanguri, V.K. and V. Nose, *Transthyretin amyloid goiter in a renal allograft recipient*. Endocr Pathol, 2008. **19**(1): p. 66-73.
334. Hamed, G., et al., *Amyloid goiter. A clinicopathologic study of 14 cases and review of the literature*. Am J Clin Pathol, 1995. **104**(3): p. 306-12.
335. Coca-Pelaz, A., et al., *Multifocal papillary thyroid carcinoma associated with primary amyloid goiter*. Auris Nasus Larynx, 2011.
336. Nessim, S. and M. Tamilia, *Papillary thyroid carcinoma associated with amyloid goiter*. Thyroid, 2005. **15**(4): p. 382-5.
337. Coli, A., et al., *Papillary carcinoma in amyloid goitre*. J Exp Clin Cancer Res, 2000. **19**(3): p. 391-4.
338. Ozdemir, B.H., B. Akman, and F.N. Ozdemir, *Amyloid goiter in Familial Mediterranean Fever (FMF): a clinicopathologic study of 10 cases*. Ren Fail, 2001. **23**(5): p. 659-67.
339. Bando, Y., et al., *Painless thyroiditis associated with severe inflammatory reactions in amyloid goiter: a case report*. Endocr J, 2001. **48**(3): p. 323-9.
340. Bryer-Ash, M., et al., *Early thyrotoxic thyroiditis after radiotherapy for tonsillar carcinoma*. Arch Otolaryngol Head Neck Surg, 2001. **127**(2): p. 209-11.
341. Espiritu, R.P. and D.S. Dean, *Parathyroidectomy-induced thyroiditis*. Endocr Pract, 2010. **16**(4): p. 656-9.
342. McDermott, A., C.V. Onyeaka, and M. Macnamara, *Surgery-induced thyroiditis: fact or fiction?* Ear Nose Throat J, 2002. **81**(6): p. 408-10.
343. Blenke, E.J., G.A. Vernham, and G. Ellis, *Surgery-induced thyroiditis following laryngectomy*. J Laryngol Otol, 2004. **118**(4): p. 313-4.